

## Task Force Report

# Guidelines on diagnosis and management of acute pulmonary embolism<sup>1</sup>

*Task Force on Pulmonary Embolism, European Society of Cardiology<sup>2</sup>:*

*Core Writing Group:* A. Torbicki (*Chairman*), E. J. R. van Beek (*Editor*), B. Charbonnier, G. Meyer, M. Morpurgo, A. Palla and A. Perrier

*Members:* N. Galie, G. Gorge, C. Herold, S. Husted, V. Jezek, W. Kasper, M. Kneussl, A. H. Morice, D. Musset, M. M. Samama, G. Simonneau, H. Sors, M. de Swiet and M. Turina

*Internal reviewers:* G. Kronik, J. Widimsky

<b>Table of contents</b>	1301	nucleus of the Working Group on Pulmonary Circulation and Right Ventricular Function and approved by the ESC Board at its meeting on 17 June 1997 upon the recommendation of the Committee for Scientific and Clinical Initiatives.
<b>Preamble</b>	1301	
<b>Introduction</b>	1302	
<b>Epidemiology and predisposing factors</b>	1302	
<b>Pathophysiology</b>	1304	
<b>Natural history and prognosis</b>	1305	
<b>Diagnosis</b>		
<b>Clinical presentation and clinical evaluation of pulmonary embolism</b>	1306	
<b>Lung scintigraphy</b>	1307	
<b>Pulmonary angiography</b>	1309	
<b>Spiral computed tomography</b>	1311	
<b>Echocardiography</b>	1312	
<b>Detection of deep vein thrombosis</b>	1314	
<b>D-dimer</b>	1315	
<b>Diagnostic strategies</b>	1315	
<b>Treatment</b>		
<b>Haemodynamic and respiratory support</b>	1317	
<b>Thrombolytic treatment</b>	1318	
<b>Surgical embolectomy</b>	1320	
<b>Anticoagulant therapy</b>	1321	
<b>Venous filters</b>	1324	
<b>Specific problems</b>		
<b>Diagnosis and treatment of PE in pregnancy</b>	1325	
<b>References</b>	1326	

### Preamble

Presented Guidelines were prepared by the ESC Task Force on Pulmonary Embolism, as suggested by the

*Correspondence:* A. Torbicki, Department of Chest Medicine, Institute of Tuberculosis and Lung Diseases, Warszawa, Poland.

<sup>1</sup>This document has been reviewed by members of the Committee for Scientific and Clinical Initiatives and by members of the Board of the European Society of Cardiology (see Appendix 1), who approved the document on 14 April 2000. The full text of this document is available on the website of the European Society of Cardiology in the section 'Scientific Information', Guidelines.

<sup>2</sup>For affiliations of Task Force Members see Appendix 2.

This Task Force consists of 21 Members, including representatives of the European Respiratory Society, the European Association of Radiology, and an advisory body consisting of two Internal Reviewers. The Members were appointed by the Board of the ESC upon suggestions from the Working Group and from the Boards of Scientific Societies, invited to contribute to the development of the guidelines on pulmonary embolism. The Chairman and seven of the Members of the Task Force formed a Core Writing Group (CWG), which included an Editor, responsible for preparation of the final document. The Task Force Members met in September 1998 in Vienna and the Core Writing Group in May 1999 in Warsaw and in January 2000 in Paris. In addition, controversial issues were presented and discussed with the Pulmonary Circulation Group of the European Respiratory Society during an open Workshop organized at the ERS annual Congress in Geneva, in September 1998.

Review of the literature and position papers were prepared by the Members according to their area of expertise. Their contributions were then posted on the Task Force WebBoard and submitted to discussion over the internet. A second phase consisted of preparation and editing of the consecutive versions of the Guidelines by the CWG, as discussed at the two consecutive meetings as well as over the internet. At the request of the Committee for Scientific and Clinical Initiatives, the Task Force Chairman reported to the Congress of the ESC in August 1999, indicating key points of the emerging guidelines.

Finally, the document was distributed for correction and endorsement to all Members and independently reviewed for consistency by Internal Reviewers. Effort was made to include all relevant evidence relating to the

diagnosis and treatment of pulmonary embolism. The Guidelines were developed with the help of a budget assigned to the Task Force by the European Society of Cardiology and without the involvement of any commercial organization. The list of all contributors is given in the Appendix.

## Introduction

Pulmonary embolism (PE) is a major international health problem with an annual estimated incidence of over 100 000 cases in France, 65 000 cases among hospitalized patients in England and Wales, and at least 60 000 new cases per year in Italy. The diagnosis is often difficult to obtain and is frequently missed. Mortality in untreated PE is approximately 30%, but with adequate (anticoagulant) treatment, this can be reduced to 2–8%. Deep vein thrombosis (DVT) and PE are common causes of illness and death after surgery, injury, child-birth and in a variety of medical conditions<sup>[1,2]</sup>. Nevertheless numerous cases go unrecognized and hence untreated, with serious outcomes. Indeed, the prevalence of PE at autopsy (approximately 12–15% in hospitalized patients) has not changed over three decades<sup>[3]</sup>. As modern medicine improves the longevity of patients with malignancy and cardiac and respiratory disease, PE may become an even more common clinical problem.

In the immediate course, PE may be fatal: the recent ICOPER study<sup>[4]</sup>, which included 2454 consecutive patients with acute PE observed in 52 hospitals, revealed a cumulative mortality at 3 months as high as 17.5%. Sometimes PE represents the 'coup de grace' that kills a patient already fated to die. However, 'preventable' deaths range from 27% to 68% of various autopsy series<sup>[5]</sup>. In the long-term, there is the risk of developing pulmonary hypertension from recurrent embolism or the absence of reperfusion of the pulmonary vasculature<sup>[6]</sup>.

For clinical purposes this Task Force suggests that PE can be classified into two main groups: massive and non-massive. Thus, massive PE consists of shock and/or hypotension (defined as a systolic blood pressure <90 mmHg or a pressure drop of  $\geq 40$  mmHg for >15 min if not caused by new-onset arrhythmia, hypovolemia or sepsis). Otherwise non-massive PE can be diagnosed. A subgroup of patients with non-massive PE may be identified by echocardiographic signs of right ventricular hypokinesis. The Task Force proposes that this subgroup be called submassive, because there is growing evidence that the prognosis of this patient group may be different from those with non-massive PE and normal right ventricular function.

### Epidemiology and predisposing factors

Estimated rates for DVT and PE in population-based studies had been reported in only a few countries, and

available data must be analysed carefully, because different diagnostic codes and criteria can be applied<sup>[7]</sup>. The annual incidence for DVT and PE in the general population of the Western World may be estimated at 1.0 and 0.5 per 1000 respectively<sup>[8]</sup>. The number of clinically silent non-fatal cases cannot be determined. The use of death certificates with a diagnosis of PE is extremely inaccurate<sup>[9]</sup>. Furthermore, discrepancies between clinical diagnosis and autopsy findings are well known.

Unsuspected PE in patients at post-mortem has not diminished, even among individuals who die from acute massive or submassive PE<sup>[2,10]</sup>. In autopsy studies, the prevalence of unsuspected PE, either fatal or contributing to death, ranges from 3% to 8%<sup>[3,11–14]</sup>.

A meta-analysis of 12 post-mortem studies carried out from 1971 through 1995 showed that more than 70% of major PEs had been missed by the clinician<sup>[2,15]</sup>. However, because necropsy is not systematically performed, autopsy studies do little to elucidate the prevalence of venous thromboembolic disease (VTE) or death by PE. In clinical studies, most cases of PE occur between ages 60 and 70, compared to between 70 and 80 years in autopsy series<sup>[12–18]</sup>.

The main primary and secondary risk factors responsible for VTE are summarized in Table 1<sup>[19,20]</sup>. Various factors may obviously act together, but a recent French multicentre registry<sup>[18]</sup> revealed that almost one in two cases of PE and DVT occurred in the absence of a classical predisposing factor.

Congenital predisposition to thrombosis is considered to be a rare condition, but the true prevalence is unknown. It should be seriously considered in patients defined as having had a documented unexplained thrombotic episode below the age of 40, recurrent DVT or PE and a positive family history<sup>[6]</sup>. The most common genetic defects that have been identified are: resistance to activated protein C (which is caused by a point mutation of factor V in 90% of cases)<sup>[21,22]</sup>, factor II 20210A mutation<sup>[23]</sup>, hyperhomocysteinemia<sup>[24,25]</sup> and deficiencies of antithrombin III, protein C and protein S<sup>[26,27]</sup>.

The incidence rates of DVT and PE increase with age<sup>[28]</sup>, but this trend may be due to an underlying relationship between age and other co-morbidities, which are the actual risk factors for VTE (e.g. cancer, myocardial infarction)<sup>[29,30]</sup>.

Thromboembolic complications have been reported in 30–60% of patients with stroke (paralysed leg), in 5–35% of patients with acute myocardial infarction, and in over 12% of patients with congestive heart failure<sup>[10,15,31–33]</sup>.

As to immobilization, even short-term (one week) immobilization may predispose to VTE. The frequency of DVT in surgical patients is approximately 5% in those undergoing herniorrhaphy, 15%–30% in cases of major abdominal surgery, 50%–75% in cases of operated hip fracture, and from 50% up to 100% in spinal cord injuries<sup>[31,34]</sup>. PE is rare after isolated valve replacement; however, it is not uncommon (3%–9% of cases) after coronary bypass surgery<sup>[35,36]</sup>. About one fourth of all

**Table 1 Risk factors for venous thromboembolism (adapted from references<sup>[19,20]</sup>)**

<b>(A) Primary</b>	
Antithrombin deficiency	Protein C deficiency
Congenital dysfibrinogenemia	Factor V Leiden (APC-R)
Thrombomodulin	Plasminogen deficiency
Hyperhomocysteinemia	Dysplasminogenemia
Anticardiolipin antibodies	Protein S deficiency
Excessive plasminogen activator inhibitor	Factor XII deficiency
Prothrombin 20210A mutation	
<b>(B) Secondary</b>	
Trauma/fractures	Surgery
Stroke	Immobilisation
Advanced age	Malignancy ± chemotherapy
Central venous catheters	Obesity
Chronic venous insufficiency	Heart failure
Smoking	Long distance travel
Pregnancy/puerperium	Oral contraceptives
Crohn's disease	Lupus anticoagulant
Nephrotic syndrome	Prosthetic surfaces
Hyperviscosity (Polycythemia, Waldenstrom's macroglobulinemia)	
Platelet abnormalities	

postoperative PEs occur after hospital discharge; this rate is even greater in the subgroup of patients undergoing so-called low-risk surgery<sup>[37]</sup>.

The risk of VTE is five times greater in a pregnant woman than in a non-pregnant woman of similar age — 75% of DVT occurring ante-partum, 66% of PE occurring post partum<sup>[38]</sup>. Oral contraceptives increase the risk of DVT threefold, but the baseline incidence in young women is very low (approximately 0.3/10 000 per year)<sup>[39]</sup>. Latest results provide reasonably strong evidence that in users of third-generation oral contraceptives (containing either desogestrel or gestodene, as the progestagen component), the risk of VTE is further increased, to 1 to 2/10 000/year<sup>[40,41]</sup>. This risk may be further increased in the presence of congenital thrombophilia, such as resistance to activated protein C. Post-menopausal hormone replacement therapy (HRT), is also associated with a threefold increase in the risk of VTE, as demonstrated by large recent prospective studies<sup>[42,43]</sup>. However, the baseline risk is again low (approximately 15/10 000 women treated by HRT per year), and most experts agree that a history of VTE is not an absolute contraindication to HRT, particularly in women at high risk of coronary artery disease, unless the episode of VTE is recent (less than one year). Finally, smoking is an independent risk factor for pulmonary embolism, as shown recently in the Nurses' study<sup>[44]</sup>.

An association between VTE and overt cancer is well documented, and recent studies suggest that patients with so-called idiopathic PE develop subsequent malignant neoplasms in approximately 10% of cases<sup>[17]</sup>. However, searching for a malignancy in patients with PE requires only a careful history and physical examination, and routine tests such as chest X-ray, complete blood count, and basic laboratory. More extensive work-up is uniformly disappointing<sup>[45-47]</sup>.

With regard to the presumed origin of thromboemboli and the relationship between DVT and PE, in clinical and autopsy studies the source of thromboemboli has been detected in 50%–70% of cases, because thrombi within the calf veins are not easily diagnosed by non-invasive methods, and dissection of the veins under the knee is not routinely done post-mortem<sup>[2,16]</sup>. Furthermore, thrombus detachment and migration may be total, especially in surgical patients<sup>[48]</sup>, so that the point of origin can no longer be identified. Among those in whom the source of thromboembolism can be identified, 70%–90% have one or more thromboses in the area of the inferior vena cava, more frequently at the level of the femoral and iliac veins. Recent post-mortem data<sup>[15]</sup> show an increasing number of thromboemboli arising from the pelvic veins, namely from peri-prostatic and peri-uterine plexuses.

In approximately 10%–20% of cases, emboli arise from thrombi located in the area of the superior vena cava. Recently, upper extremity venous thrombosis has become more frequent<sup>[15,16,49,50]</sup> as a result of invasive diagnostic and therapeutic procedures (e.g. indwelling venous catheters, intravenous chemotherapeutic agents). Upper extremity venous thrombosis may be associated with PE in up to 40% of cases<sup>[52,53]</sup>. The cardiac origin of PE plays only a minor role in the overall incidence of the disease<sup>[15,53]</sup>.

A correlation between thrombosis location and the incidence and severity of PE has been demonstrated by a prospective clinical study<sup>[54]</sup>. The incidence of PE was 46% if DVT was confined to the calf, increased to 67% with involvement of the thigh, and up to 77% if the pelvic veins were involved. In severe PEs, most emboli arise from thrombi in the proximal veins. Many of these thrombi, however, originate in the calf and progress into the proximal veins before embolization<sup>[55]</sup>.

**Table 2 Haemodynamic consequences of PE**

<b>(A) Changes of pulmonary haemodynamics</b>	
Precapillary hypertension	Reduced vascular bed Bronchoconstriction Arteriolar vasoconstriction
Development of collateral vessels	Broncho-pulmonary arterial anastomoses Pulmonary arterio-venous shunts
Blood flow changes	Flow redistribution Flow resumption (lysis, etc.)
<b>(B) Changes of systemic circulation and cardiac function</b>	
Arterial hypotension	
Tachycardia	
RV overload and dilation	
Increased central venous pressure	
LV geometrical changes	
<b>(C) Changes of coronary circulation</b>	
Reduced transcoronary pressure gradient	Aortic hypotension Right atrial hypertension
Reduced flow per myocardial unit	
Relative hypoperfusion of RV subendocardium	

**Table 3 Respiratory consequences of PE**

<b>(A) Changes of respiratory dynamics</b>	
Hyperventilation	Pulmonary arterial hypertension Reduced compliance Atelectasis
Increased airway resistance	Local hypocapnia Chemical mediators
<b>(B) Changes of alveolar ventilation</b>	
Alveolar hyperventilation (hypocapnia, alkalemia) or relative alveolar hypoventilation	
<b>(C) Changes of respiratory mechanics</b>	
Reduced dynamic compliance	Decreased surfactant Atelectasis Bronchoconstriction
<b>(D) Changes of diffusing capacity</b>	
Reduced capillary blood volume Reduced membrane permeability (?)	
<b>(E) Changes of ventilation/perfusion ratio</b>	

**Summary**

- The annual incidence of DVT and PE is estimated at 1.0 and 0.5 per 1000 in the Western world, respectively.
- DVT and PE are both part of one entity: venous thromboembolism (VTE).
- Both acquired and inherited risk factors have been identified

**Pathophysiology**

Tables 2 and 3 summarize the complex and multifactorial changes of respiratory and cardiovascular functions caused by acute PE. Both the magnitude of embolization and the absence or presence of pre-existing cardiopulmonary disease<sup>[10,56]</sup> are responsible for the haemodynamic consequences of acute PE, in terms of pulmonary artery and systemic pressure, right

atrial pressure, cardiac output, pulmonary vascular resistance and input impedance, and finally coronary blood flow.

In massive PE, the increased right ventricular (RV) afterload leads to increased right ventricular myocardial work and O<sub>2</sub> consumption. The cardiac index falls despite adequate blood pressure, a constant or increasing RV preload and constant contractility. As the systemic pressure ultimately falls and the RV pressure increases, the pressure gradient between the aorta and the RV narrows. Cardiac ischaemia, however, does not entirely explain the deterioration of left ventricular output, which is also likely to be the result of the pericardial constraint in the face of RV dilatation, as well as to a leftward shift of the interventricular septum<sup>[57]</sup>. A recent study in patients with pulmonary hypertension showed that increased right ventricular afterload due to pulmonary vascular obstruction gives rise to a combination of right ventricular failure and decrease of left ventricular preload<sup>[58]</sup>. Together with the abnormal geometry of the interventricular septum, this

leads to an overall decrease of the cardiac index. It is likely that this sequence of events is more profound in acute PE, because the right ventricle is not hypertrophied and thus less able to overcome the initial increase in afterload.

In acute PE, particularly in massive PE, hypoxaemia may be due to: (a) ventilation/perfusion mismatching: the V/Q ratio, that is increased in the hypoperfused areas, may be reduced in some relatively over-perfused zones, or in atelectatic areas; (b) shunting within the lung or the heart due to either the opening of pre-existing pulmonary arterial-venous anastomoses, or to a patent foramen ovale; (c) reduced mixed venous oxygen saturation, secondary to a decreased cardiac output; (d) altered diffusion component. In most cases, these various mechanisms probably interact, and their importance also depends on the possible underlying cardiopulmonary pathology<sup>[59,60]</sup>.

Embolism without pulmonary infarction is the general rule and true pulmonary infarction the exception<sup>[48]</sup>. Pulmonary infarction is most likely to occur in patients with pre-existing left ventricular failure or pulmonary disease. Alveolar haemorrhage due to obstruction of distal pulmonary arteries and to influx of bronchial arterial blood resolves without pulmonary infarction in most patients, but may progress to infarction in those with pre-existing heart disease<sup>[61]</sup>.

#### Summary

- The haemodynamic consequences of PE are directly related to the size and number of emboli and the pre-existing cardiac and respiratory status.
- Pulmonary infarction is a relatively rare complication.

### Natural history and prognosis

It is difficult to trace the natural history of a condition that is a syndrome rather than a well-defined disease, and a complication of numerous and different afflictions. In the acute phase of DVT, once a thrombus is formed in veins, it can resolve, extend or embolize. Untreated calf DVT has a low frequency of recurrence, provided proximal extension does not occur, but inadequately treated proximal DVT carries a significant risk of recurrence<sup>[62]</sup>.

PE may occur as a single event or in the form of successive episodes. The prognosis may be influenced in the acute and post-acute phase. In the acute phase, a first attack may cause death, produce mild or severe clinical consequences or no symptoms at all. In general, anatomically large emboli pose a greater threat than small ones. In rare cases, however, embolization of the peripheral branches of the pulmonary arteries, leaving the main branches free, may produce symptoms of marked severity and even cause sudden and unexpected

death<sup>[63,64]</sup>. There is a considerable risk of recurrent PE, especially during the first 4–6 weeks<sup>[11,48,65]</sup>. This risk is greatly increased in the absence of anticoagulant therapy<sup>[66]</sup>. Hence, the short-term outcome of patients who survive an initial PE episode is influenced greatly by whether or not therapy is instituted. This action, in turn, is obviously determined by whether or not a timely diagnosis is made<sup>[66,67]</sup>. The mortality of untreated PE is 25% to 30%<sup>[66]</sup>. This figure comes from an old study, which probably recruited patients with more severe PE than recent trials and may, therefore, be an over-estimate. Nevertheless, there are no, nor will there be, alternative data, and any PE should be considered potentially fatal due to possible recurrence, whatever the clinical importance of the first episode. With adequate anticoagulant therapy, the incidence of both fatal and non-fatal recurrent PE is reduced to less than 8%<sup>[7,66]</sup>. This risk is not influenced by the presence of free-floating proximal DVT<sup>[65]</sup>.

Right ventricular afterload stress detected by echocardiography is a major determinant of short-term prognosis when PE is clinically suspected<sup>[68,69]</sup> and detection of a patent foramen ovale is a significant predictor of ischaemic stroke and morbidity in patients with major PE<sup>[70]</sup>. The prognostic significance of right-sided mobile thrombi remains uncertain<sup>[71–75]</sup>. In the largest studies, which were systematic reviews<sup>[71,72]</sup>, or registry studies<sup>[73]</sup>, a fatal outcome was reported in up to 35%–42% of patients with right-sided mobile thrombi. In one study, however, the presence of right heart thrombi did not significantly affect early and total in-hospital mortality<sup>[75]</sup>.

The onset of massive PE may be preceded in the last weeks by a number of smaller PEs, which often escape the attention of the clinician<sup>[76]</sup>. Multiple PEs and infarcts of different age (recent, organizing, and organized) are found at necropsy in 15%–60% of cases<sup>[11,48]</sup>. This finding is important, since it means that these patients suffered from successive emboli and that death might have been prevented if an early diagnosis had been made<sup>[11]</sup>.

During the post-acute phase of PE, the prognosis is largely dependent on adequate clot resolution and revascularization of the pulmonary arterial and deep venous systems. This is influenced by a range of factors, such as the presence of congenital thrombophilia, the adequacy of anticoagulant therapy and the presence of permanent risk factors. Even when patients survive their initial episode of PE, the long-term prognosis is largely determined by underlying conditions. Factors associated with higher mortality are advanced age, cancer, stroke and cardiopulmonary disease.

In some patients, investigation of dyspnoea or chronic right heart failure discloses severe pulmonary hypertension due to silent recurrent PE. This entity of chronic thromboembolic disease is distinct from acute PE, and, if untreated, usually fatal in the 2–3 years following initial detection<sup>[75,77]</sup>.

*Summary*

- Untreated VTE has a high risk of (fatal or non-fatal) recurrence.
- Anticoagulant therapy reduces the mortality in patients with PE by 75%.
- The prognosis of treated, non-massive VTE is mainly dependent on co-existing illnesses, such as malignancy or cardiovascular diseases.

**Diagnosis***Clinical presentations and clinical evaluation of pulmonary embolism*

As previously discussed, PE is a potentially fatal disorder with a range of clinical presentations (from haemodynamic instability to silent). Evaluating the likelihood of PE in an individual patient according to the clinical presentation is of utmost importance in the interpretation of diagnostic test results and selection of an appropriate diagnostic strategy. In 90% of cases, suspicion of PE is raised by clinical symptoms such as dyspnoea, chest pain or syncope, either singly or in combination. In a classic series, dyspnoea, tachypnoea, or chest pain were present in 97% of patients with PE without cardiac or pulmonary disease<sup>[78]</sup>. Similarly, in a recent series in which 25% had a previous cardiac or pulmonary disease, recent onset dyspnoea, chest pain or syncope were present in as many as 97% of patients with PE<sup>[79,80]</sup>. In 10% of cases, PE is suspected because of incidental radiological findings, either on chest X-ray or helical CT scan, in high risk situations.

Pleuritic chest pain, whether or not combined with dyspnoea, is one of the most frequent presentations of PE (Table 4)<sup>[78-80]</sup>. This pain is usually due to distal emboli causing pleural irritation, and a consolidation may be present on chest X-ray. This syndrome is often improperly named 'pulmonary infarction', although the histopathological correlate is an alveolar haemorrhage, which is only exceptionally associated with haemoptysis.

Isolated dyspnoea of rapid onset is usually due to more central PE, not affecting the pleura. It may be associated with substernal angina-like chest pain, probably representing right ventricular ischaemia. The haemodynamic consequences are more prominent than in the 'pulmonary infarction' syndrome. Occasionally, the onset of dyspnoea may be very progressive, over several weeks, and the diagnosis of PE is evoked by the absence of other classic causes of progressive dyspnoea. In patients with pre-existing heart failure or pulmonary disease, worsening dyspnoea may be the only symptom indicative of PE.

Finally, syncope or shock is the hallmark of central PE with severe haemodynamic repercussions, and is accompanied by signs of haemodynamic compromise and reduced heart flow, such as systemic arterial hypo-

**Table 4 Signs, symptoms and findings in suspected PE (from references<sup>[78,80]</sup>)**

	PE (n=219)	no PE (n=546)
<b>Symptoms</b>		
Dyspnoea	80%	59%
Chest pain (pleuritic)	52%	43%
Chest pain (substernal)	12%	8%
Cough	20%	25%
Haemoptysis	11%	7%
Syncope	19%	11%
<b>Signs</b>		
Tachypnoea ( $\geq 20/\text{min}$ )**	70%	68%
Tachycardia ( $>100/\text{min}$ )	26%	23%
Signs of DVT	15%	10%
Fever ( $>38.5^\circ\text{C}$ )	7%	17%
Cyanosis	11%	9%
<b>Chest X-ray</b>		
Atelectasis or infiltrate	49%	45%
Pleural effusion	46%	33%
Pleural-based opacity (infarction)	23%	10%
Elevated diaphragm	36%	25%
Decreased pulmonary vascularity	36%	6%
Amputation of hilar artery*	36%	1%
<b>Blood gases</b>		
Hypoxaemia**	75%	81%
<b>Electrocardiogram</b>		
Right ventricular overload*	50%	12%

\*Only observed in series of reference<sup>[78]</sup>.\*\*Only observed in series of reference<sup>[80]</sup>.

tension, oliguria, cold limb extremities and/or clinical signs of acute right heart failure.

The presence or absence of risk factors for VTE is essential in the evaluation of the likelihood of PE. Moreover, it should be recognized that the risk of PE increases with the number of risk factors present. However, PE does occur frequently in individuals without any risk factors<sup>[18]</sup>. Individual clinical signs and symptoms are not very helpful, as they are neither sensitive nor specific (Table 4). Chest X-ray is usually abnormal, and the most frequently encountered findings are plate-like atelectasis, pleural effusion or elevation of a haemidiaphragm. However, these signs are not very specific and the chest X-ray is mainly useful to exclude other causes of dyspnoea and chest pain. In the PISAPED study<sup>[80]</sup>, amputation of a hilar artery, oligemia and a pleural-based wedge-shaped infiltrate appeared to be closely associated with PE, and were present in 15% to 45% of patients. However, this contradicts the findings from previous series<sup>[78]</sup>, and the chest X-rays in the PISAPED study<sup>[80]</sup> were interpreted by six pulmonary physicians, all of them experts in the field of PE diagnosis. Hence, the practical value of these signs in other settings remains to be demonstrated. PE is generally associated with hypoxaemia, but up to 20% of patients with PE have a normal arterial oxygen pressure ( $P_aO_2$ ). Since most are also hypocapnic, it was hoped that the oxygen alveolo-arterial difference ( $D_{(A-a)O_2}$ ) would be more sensitive for PE than  $P_aO_2$ , but clinical trials were

disappointing<sup>[79]</sup> revealing that 15 to 20% of patients with proven PE also have a normal  $D_{(A-a)}O_2$ . Finally, ECG signs of right ventricular overload ( $S_1Q_3$  pattern, inversion of T waves,  $V_1$  to  $V_3$  leads, right bundle branch block) may be helpful. Nevertheless, such changes are generally associated with the more severe forms of PE, and may be found in right ventricular strain of any cause.

Since the diagnostic value of individual symptoms, signs and common test findings is poor, one could conclude that clinical evaluation is useless in suspected PE. However, a large body of data contradicts this. Indeed, the combination of these variables, either empirically or implicitly by the clinician<sup>[83-85]</sup>, or by a prediction rule<sup>[80,86-88]</sup>, allows a fairly accurate indication of suspected PE patients in three broad so-called clinical or pre-test probability categories. Table 5 shows the predictive value of clinical assessment by various methods. To recognize patients with a high likelihood of the disease, prediction rules appear to be more accurate than empirical evaluation. However, the clinical usefulness of distinguishing between an intermediate and high clinical probability may be limited.

Clinical probability has been used in combination with lung scans to rule out clinically significant PE. A recent analysis of a database of 1034 consecutive patients suspected of PE in the emergency ward showed that the 3-month thromboembolic risk was very low (1.7%, 95% CI 0.4 to 4.9) in 175 suspected PE patients not treated on the grounds of low empirical clinical probability and a non-diagnostic lung scan, provided lower limb venous compression ultrasonography (US) did not show a proximal deep vein thrombosis (DVT)<sup>[84]</sup>. This combination was found in 21% of patients, who, therefore, did not undergo an angiogram. Similarly, Canadian investigators used a low to moderate score of the clinical probability of PE to avoid angiography in 702 of 1239 (57%) patients with a non-diagnostic scan and normal serial US (see diagnostic strategies), and the 3-month thromboembolic risk was only 0.5% (95% CI 0.1 to 1.3)<sup>[86]</sup>.

As shown in Table 5, the clinician must choose between empiricism and two prediction rules to assess the clinical probability of PE. The obvious advantage of a prediction rule is to allow a standardized and explicit evaluation. The reader should, however, be aware that subjectivity carries a great weight in one of the prediction rules<sup>[86]</sup>. Indeed, an important element in the score is the decision whether another diagnosis is as, or more likely, than PE in a given patient. Moreover, a prediction rule should fulfil rigorous methodological standards in order to be valid and transferable to clinical practice<sup>[89,90]</sup>. These standards have been met by one series<sup>[86]</sup>, including external validation and clinical usefulness evaluation, but not by the PISAPED study<sup>[80]</sup>. Besides, this score is only valid in combination with specific lung scan criteria developed by the PISAPED study<sup>[91]</sup>, which still awaits external validation. Finally, practical experience shows that, when confronted by a discrepancy between empirical evaluation and the

probability given by a score, the clinician generally chooses to rely on his or her own experience.

#### Summary

- PE has a wide range of clinical presentation.
- A reasonable clinical suspicion is required to avoid missing the diagnosis of PE.
- First line diagnostic tests, such as ECG, chest X-ray and blood-gas analysis are indicated to assess clinical probability of PE and general condition of the patient.
- Clinical evaluation is accurate to discriminate a subgroup of patients with a low likelihood of PE.
- Clinical probability may be estimated empirically or explicitly by a prediction rule.
- Patients with a low clinical probability of PE, no lower limb deep vein thrombosis and a non-diagnostic lung scan have a very low risk of PE.

#### Lung scintigraphy

Lung scintigraphy has a pivotal role to play in the diagnostic management of suspected pulmonary embolism. The reasons for this are twofold: it is a non-invasive diagnostic technique and it has been evaluated in extensive clinical trials. It has been proven extremely safe to apply, and few allergic reactions have been described.

Lung scintigraphy consists of two components: perfusion and ventilation imaging. Imaging is performed in at least six projections; the most commonly used are anterior, posterior, left lateral, left anterior oblique, right lateral and right anterior oblique. For perfusion imaging,  $^{99m}\text{Tc}$ -labelled macroaggregates of albumin (MAA) are injected intravenously with the patient supine and breathing deeply<sup>[92]</sup>. The result is that the particles are trapped uniformly in the pulmonary capillary bed, where a fraction of capillaries will be temporarily obstructed<sup>[93]</sup>. In case of occlusion of pulmonary arterial branches, the capillary bed of the more peripheral vascular bed will not receive particles, rendering the area 'cold' on subsequent images. Ventilation imaging may be performed with a variety of agents, including  $^{81m}\text{Kr}$ -Krypton,  $^{99m}\text{Tc}$ -diethylene triamine penta-acetic acid (DTPA) aerosols,  $^{133}\text{Xe}$ -Xenon and  $^{99m}\text{Tc}$ -labelled carbon particles (Technegas)<sup>[94]</sup>.

Classification of lung scintigraphy has been a matter of debate over several years. The first attempts to arrive at a classification stem from McNeil<sup>[95]</sup> and Biello<sup>[96]</sup>. More recently, a large trial was performed in North America (PIOPED), which came up with an even more sophisticated classification<sup>[85]</sup>. Due to the fact that PE were angiographically proven in 16% of patients who were classified as low probability, this classification has received criticism<sup>[97]</sup>. Subsequently, the PIOPED criteria were revised to try and improve the predictive values of lung scintigraphy<sup>[98,99]</sup>.

**Table 5 Assessment of clinical probability of pulmonary embolism (PE): comparison of various methods**

Study	Wells <i>et al.</i> <sup>[86]</sup>	Miniati <i>et al.</i> <sup>[80]</sup>	Perrier <i>et al.</i> <sup>[83]</sup>	PIOPED <sup>[85]</sup>
Patients included	ER and inpatients	ER and inpatients	ER	ER and inpatients
Number of patients*	1239	250	1034	887
Prevalence of PE	17%	41%	28%	28%
Means of assessment of clinical probability	prediction rule‡	prediction rule†	empirical	empirical
PE prevalence in clinical probability subgroups				
Low probability	3% (2–5)	11% (6–16)	8% (6–11)	9% (6–14)
Intermediate probability	28% (23–32)	—	36% (32–40)	30% (26–34)
High probability	78% (70–86)	91% (84–96)	67% (57–76)	68% (57–77)
% patients with a low clinical probability of PE	60%	62%	41%	26%
Prospective validation of prediction rule	yes	yes	—	—
Outcome of clinical use assessed	yes	no	yes	no

\*In the validation sample in case of a prediction rule.

†Rule development based on expert consensus and a multivariate analysis.

‡Rule development based on expert consensus only.

Numbers between parentheses represent 95% confidence intervals.

ER=emergency room.

The PISAPED trial used a more clinically orientated classification solely using perfusion lung scintigraphy to try and eliminate indeterminate lung scan results<sup>[91]</sup>. Using this classification, one of the principle PIOPED investigators was able to correctly identify 91% of patients with proven PE and exclude 80% of those in whom PE was refuted by angiography. This approach can be extended to the classification of perfusion-ventilation lung scintigraphy, which may be classified into three categories: PE excluded (normal), PE proven (high probability, defined as at least one segmental or greater perfusion defect with locally normal ventilation or chest X-ray findings) and PE neither excluded nor proven (non-diagnostic)<sup>[100–103]</sup>.

The results of lung scans should be integrated with the clinical suspicion of the referring physician, as demonstrated in several large studies<sup>[85,91,99]</sup>. Hence, if the lung scan findings contradict clinical suspicion (low clinical probability of PE and high probability lung scan, or high clinical suspicion and normal lung scan), further diagnostic tests may be warranted<sup>[101]</sup>. However, such combinations of findings are rare.

The inter-observer and intra-observer disagreement for lung scan reporting amounts to approximately 10% to 20%, and is independent of the classification used<sup>[104–107]</sup>. It was demonstrated that consistent application of an anatomical lung segment chart significantly improved the consistency of reporting<sup>[107,108]</sup>.

Three studies have specifically assessed the validity of a normal perfusion lung scan<sup>[109–111]</sup>. One of these studies was a retrospective analysis of 68 patients<sup>[109]</sup>, whereas the remaining two studies were prospective studies in patients with clinically suspected PE and a normal perfusion scan in whom anticoagulants were withheld<sup>[110,111]</sup>. Hence, data on 693 patients exist, which showed one patient with a fatal PE and one patient with a non-fatal thromboembolic event during at least 3 months of follow-up for a total event rate of 0.2% (95% CI: 0.1%–0.4%). Thus, it is regarded as safe practice to withhold anticoagulant therapy in patients with a nor-

mal perfusion scan. An exception to this rule may be a patient with a very high clinical probability for the presence of thromboembolism<sup>[101,102]</sup>.

Several studies have compared perfusion-ventilation lung scintigraphy with pulmonary angiography<sup>[85,96,100,112–117]</sup>. In a total of 350 patients with at least one segmental perfusion defect and focally normal ventilation, the positive predictive value (PPV) was 88% (95% CI: 84%–91%). This PPV constitutes sufficient proof for the presence of PE to warrant the institution of long-term anticoagulant therapy in most patients. It may be appropriate to perform pulmonary angiography, if the clinical suspicion is low, and the risk of bleeding complications is high (e.g. in the postoperative period)<sup>[101,102]</sup>.

In a total of 12 studies, 1529 patients in whom neither a normal nor a high probability lung scan was obtained (no matter what criteria were used) underwent pulmonary angiography<sup>[85,96,100,112–120]</sup>. PE was proven in 385 patients (25%; 95% CI: 24%–28%). Hence, these lung scan abnormalities are insufficient to base any type of treatment decision on (i.e. non-diagnostic result) and further diagnostic tests are required.

The PISAPED study exclusively used perfusion lung scintigraphy and chest radiography and incorporated the clinical suspicion to reach a diagnosis of normal, quasi-normal, PE unlikely, and PE likely<sup>[91]</sup>. Pulmonary angiography yielded a definitive result in 386 of 607 patients with abnormal perfusion lung scans, while a further four patients died prior to angiography and underwent post-mortem examination. PE was shown in 236 patients (lung scan positive in 217, sensitivity 92%, PPV 92%), while PE was excluded in 154 patients (lung scan normal in 134, specificity 87%, NPV 88%). Furthermore, follow-up was performed up to one year in the majority of patients. When taking clinical suspicion, lung scan data and follow-up data into consideration, it is clear that this approach increased the number of patients with a definitive diagnosis, and that pulmonary angiography could be greatly reduced.

However, this study requires confirmation in a management study.

A final topic of interest refers to patients with pre-existing chronic obstructive pulmonary diseases (COPD). In these patients, the lung perfusion may be compromised due to reactive vasoconstriction from airway obstruction. Although lung scan findings appear to be non-diagnostic more often in patients with COPD, there still remains a role for lung scintigraphy in this sub-group<sup>[121]</sup>.

#### Summary

- Approximately 25% of patients with suspected PE will have the diagnosis refuted by a normal perfusion lung scan and anticoagulants may be safely withheld.
- Around 25% of patients with suspected PE will have a high probability lung scan and anticoagulant therapy may be instituted.
- The remaining patients will require further diagnostic tests as part of a wider diagnostic strategy.

### Pulmonary angiography

Forssmann was the first to describe right-sided heart catheterization in 1929, which he performed first on himself (sic!) and later in dogs<sup>[122]</sup>. Selective pulmonary angiography was not performed until 25 years later. Since then, several advances have been made, such as the catheter introduction technique by Seldinger, the development of rapid imaging equipment (film-changers), digital subtraction angiography (DSA), the introduction of the pigtail catheter, the application of safer contrast agents and catheter and guide-wire materials. These improvements have led to pulmonary angiography being a relatively safe procedure. This increased safety is highlighted, when comparing studies, which were published during the period 1960–1980<sup>[123–126]</sup> with those that were published during this decade<sup>[127–132]</sup>. This shows a 50% reduction in fatal and a fourfold reduction in non-fatal complications<sup>[133]</sup>. Currently, the risk of fatal or serious complications is approximately 0.1% and 1.5%, respectively.

Indications to perform pulmonary angiography differ with the availability of non-invasive diagnostic tests, the clinical status of the patient and the necessity to get an absolute diagnosis. It is generally accepted that pulmonary angiography is the method of choice in all patients in whom non-invasive tests are either inconclusive or not available. Angiography may also be indicated in the rare situation of an extremely high bleeding risk (for instance after neurosurgery) and an abnormal, even high probability lung scan. Finally, angiography may be indicated in patients with (relative) contraindications for thrombolytic or heparin therapy.

Contraindications for pulmonary angiography have declined over the years. No absolute contraindications

currently exist, although several relative contraindications should be noted<sup>[133]</sup>. These include: allergy to iodine containing contrast agents, impaired renal function, left bundle branch block, severe congestive heart failure, and severe thrombocytopenia. Severe pulmonary hypertension (mean PAP >40mmHg) increases the risks of complications, but by reducing amounts of contrast and increasing linear rise this is well within reasonable limits. Several studies have reported on the safety of pulmonary angiography in large patient groups with pre-existing pulmonary hypertension<sup>[129,134,135]</sup>. Albeit that these contraindications are relative, they are usually part of the decision not to perform pulmonary angiography. However, the general condition of the patient is mostly the deciding factor, as demonstrated in two recent studies where pulmonary angiography could not be performed in 10%–20% of patients who were scheduled for the procedure<sup>[127,130]</sup>.

The technique of pulmonary angiography is well-known. Patients who are entering an angiography suite to undergo pulmonary angiography need to be monitored. Furthermore, oxygen should be freely available. Monitoring can include pulse oxymeter, automated blood pressure and pulse measurement device and ECG. Rhythm disorders are common, but usually self-limited, during passage of the right heart chambers. Anyone performing pulmonary angiography should be capable of recognizing the main rhythm disorders and know how to treat them. A pigtail catheter, varying in size from 5F to 7F, is generally used<sup>[136]</sup>. Balloon catheters may be helpful to pass a large right atrium/ventricle. Furthermore, they may be able to reduce contrast load in selected patients by using occlusion<sup>[128]</sup>. Introducer sheaths are not required. Guide-wires are not essential, but atraumatic wires may be used<sup>[130,137]</sup>.

Low-osmolar contrast agents, with a minimum of 300 mg iodine . ml<sup>-1</sup>, should be used for pulmonary angiography. Although the safety of any of the available low-osmolar contrast agent has been shown, non-ionic agents are generally preferred due to better tolerance by the patient, reduced cough reflex and less nausea, which all contribute to better images on the basis of less patient movement<sup>[138–140]</sup>.

Digital subtraction angiography is increasingly replacing fast film exchange systems. The spatial resolution of conventional film remains superior to that of DSA. However, recent studies suggest that the use of cinematic review and work station manipulation are beneficial for the interpretation of pulmonary angiography. These benefits are noticeable in terms of inter-observer variation, adequacy of opacification of smaller branches and diagnostic performance<sup>[137,141,142]</sup>. Hence, it is warranted that DSA should replace cut film angiography as the method of choice for arteriography of the pulmonary arteries.

It was previously suggested that intravenous digital subtraction angiography could adequately depict or exclude pulmonary emboli<sup>[143]</sup>. This would have the benefit of peripheral contrast injection. Initially, a

sensitivity of 75%–100% and a specificity of 96%–100% were obtained, but these figures used lung scintigraphy as the reference method<sup>[143]</sup>. Later, it was shown that intravenous contrast is diluted, resulting in insufficiently opacified segmental and subsegmental branches, and a suboptimal sensitivity and specificity<sup>[144,145]</sup>. Hence, it should be stressed that intra-arterial injection of contrast is a prerequisite for adequate interpretation of pulmonary angiography.

Using the Seldinger technique, both a brachial, jugular and (right) femoral venous approach may be applied. Once the catheter is in the pulmonary trunk, a trial injection of contrast should be administered by hand to check for large central emboli. If present, it is advised that a full X-ray series be obtained with contrast injection in the right ventricle. However, if the trial injection does not reveal central emboli, the catheter may be advanced into the right or left pulmonary artery. A small bolus injection must be given prior to obtaining a full radiographic series to ascertain that the catheter tip is positioned adequately, and is not wedged into a small side branch or in a subintimal position<sup>[133]</sup>.

Using an injection into the main pulmonary artery, adequate opacification of all segmental and subsegmental branches is usually obtained. However, in patients with atelectasis or with pain-related splinting of the diaphragm, it may be necessary to perform more selective catheterization<sup>[133]</sup>. Contrast injection should be performed using an automated injector system, a rate of  $20 \text{ ml} \cdot \text{s}^{-1}$  at a pressure of 600 PSI ( $42 \text{ kg} \cdot \text{cm}^{-2}$ ). In patients with pulmonary hypertension or with more selective injections, the total amount of contrast is reduced to 10–15  $\text{ml} \cdot \text{s}^{-1}$  for 2 s<sup>[133]</sup>.

A minimum of two radiographic series is required. The standard projections used are anterior–posterior, and 20° to 40° left and right posterior oblique for the left and right lung, respectively<sup>[146]</sup>. However, additional series, such as lateral or magnification views, may be required.

Haemodynamic measurements are an integral part of pulmonary angiography. Nevertheless, some people feel that they may be omitted since echocardiography is presently able to adequately measure pressures non-invasively. If pulmonary hypertension is diagnosed, less contrast at lower pressure may be injected. Alternatively, one could resort to super-selective catheterization of lobar or segmental arteries. These measures will reduce the risks of acute right ventricular overload in patients with pulmonary hypertension<sup>[133–135]</sup>.

The diagnostic criteria for acute PE were defined over 30 years ago<sup>[123,147]</sup>. Large studies have validated these criteria subsequently. There are direct angiographic signs of PE, which are: complete obstruction of a vessel (preferably with concave border of the contrast column) or a filling defect<sup>[123,127,148]</sup>. These criteria have shown the reliability of various studies which assessed intra- and inter-observer variation<sup>[127,137,149]</sup>. More recently, it was demonstrated that the same criteria may be applied in DSA<sup>[137,141,142]</sup>. However, one should be

aware of the fact that the reliability of pulmonary angiography decreases with diminishing calibre of the vessels, i.e. the interpretation is more difficult after the subsegmental level<sup>[149]</sup>. Patient selection may also influence the diagnostic accuracy of pulmonary angiography. In 140 patients with a non-diagnostic lung scan who underwent angiography, the kappa values of cut-film angiography ranged between 0.28 and 0.59, which increased to a range of 0.66–0.89 for DSA<sup>[137]</sup>. Nevertheless, these values were lower than those obtained in non-selected patient populations<sup>[127,149]</sup>, possibly because underlying pulmonary and cardiac diseases had a negative influence on the interpretation of images.

Indirect signs of PE may be slow flow of contrast media, regional hypoperfusion and delayed or diminished pulmonary venous flow. One should be aware that these signs could direct one's attention to a specific region, but none of these signs have been validated. One should not diagnose PE in the absence of direct angiographic signs.

PEs vary greatly in size, and distribution of emboli may be important for other, less invasive modalities. In one study in 76 patients with proven PE, emboli were located exclusively in subsegmental arterial branches in 23 (30%) patients<sup>[150]</sup>. In the PIOPED study, 6% of all patients who underwent pulmonary angiography had their emboli limited to subsegmental vessels, but this percentage increased to 17% of patients with a low probability lung scan result<sup>[85]</sup>. Similarly, in a selected group of 140 patients who underwent angiography following a non-diagnostic lung scan, the largest emboli were in subsegmental vessels in three out of 20 patients (15%) in whom PE was proven<sup>[130]</sup>.

Pulmonary angiography is generally regarded as the reference method for the diagnosis and (maybe more importantly) the exclusion of PE. This does not mean that pulmonary angiography is infallible. Since angiography is the reference method, the sensitivity and specificity of this technique cannot be formally evaluated. The clinical validity of a normal pulmonary angiogram was assessed in five well-designed studies<sup>[85,112,130,147,151,152]</sup>. Anticoagulants were withheld in 840 patients with clinically suspected PE in whom a normal pulmonary angiogram was obtained. All patients were followed-up for a minimum of 3 months. Recurrent VTE was demonstrated in 16 patients (1.9%; 95% CI: 1.4%–3.2%), three of them fatal (0.3%; 95% CI: 0.09%–1.08%). Hence, it is regarded safe clinical practice to withhold anticoagulants in patients with chest symptoms and a normal pulmonary arteriogram.

From these data, it may be concluded that the sensitivity of pulmonary angiography is in the region of 98%. Similar, the specificity is thought to be between 95% and 98%. This figure is slightly lower than the sensitivity due to other illnesses, which may mimic the criteria for PE, such as obstruction of an artery due to tumour.

*Summary*

- The safety of pulmonary angiography has improved over the past decade.
- Pulmonary angiography is the reference method, but should be reserved for patients in whom non-invasive diagnostic tests remain indeterminate.
- It is safe to withhold anticoagulant therapy in patients with suspected PE and normal angiogram.
- Indirect signs of PE on angiography have not been validated.

*Spiral computed tomography (sCT)*

In recent years, technical advances in CT have prompted enormous interest in the use of this technique for the diagnosis of PE. Two methods, namely electron beam tomography and helical or spiral CT (sCT) angiography have revolutionized the approach to the evaluation of patients with suspected PE. In sCT, imaging acquisition times and total scan times are significantly reduced compared to conventional CT and the pulmonary vascular tree can be scanned at peak contrast opacification. Therefore, unlike V/Q scanning, modern CT imaging techniques enable the direct visualization of pulmonary emboli within the pulmonary arteries<sup>[153,154]</sup>. Because of its increasing availability, this presentation will focus on sCT angiography and discuss technique and image interpretation and its value in the diagnosis of PE.

The design of the optimal imaging technique to the diagnosis of PE varies from institution to institution. Despite this heterogeneity, the general guidelines for imaging of the pulmonary artery can be specified. In most institutions, sCT angiography is performed as a single contrast series through the thorax. About 90% of patients investigated for suspected PE can hold their breath sufficiently long for single breath-hold data acquisition, while shallow breathing is used in the remainder<sup>[155]</sup>.

The lung volume scanned should be large enough to include subsegmental vessels to allow for a meticulous analysis. To achieve this, CT scanning should comprise a lung volume between the top of the aortic arch and the dome of the diaphragm. In most institutions, caudo-cranial scanning direction is preferred. Breathing artifacts are significantly less intensive in the upper compared to the lower portions of the lung, when the patient breathes during the final phase of data acquisition. Alternatively collimation and table feed may be increased. Finally, the administration of pure oxygen prior to the CT scan has been advocated to improve breath-hold time.

Most commonly, imaging is performed with 120 kV, 210–250 mAs, a slice thickness of 3 mm, a table speed of  $5 \text{ mm} \cdot \text{s}^{-1}$ , (pitch 1.7) and a reconstruction index of 2 mm. Narrowing the collimation to 2 mm improves the

analysis of subsegmental vessels<sup>[156]</sup>. The advantage of increased pitch is that it allows for scanning of larger volumes without loss of resolution<sup>[157]</sup>. In obese patients, a slice thickness of 5 mm, a table speed of 5 mm and a reconstruction index of 3 mm should be used to improve signal–noise ratio.

The scan delay, i.e. the time interval between contrast injection and data acquisition depends on the patient's clinical status. In most patients, a scan delay of 15 s is sufficient to allow for optimal vessel opacification. In patients with a history, signs and symptoms of pulmonary arterial hypertension, right ventricular failure and overall cardiac failure, scan delay may vary between 15 and 30 s and should be determined individually. In the presence of a central venous catheter, a delay of 5 s is suitable.

The administration of contrast material requires the use of a power injector. In most institutions, non-ionic contrast media are preferred. Two basic contrast administration strategies can be specified, each with good results. The low concentration–high flow approach injects 120–150 ml of contrast medium with 120–200 mg iodine  $\cdot \text{ml}^{-1}$  with a flow of 4 to  $5 \text{ ml} \cdot \text{s}^{-1}$ <sup>[153,158,159]</sup>. The high concentration–low flow technique uses 100–120 ml of contrast medium with 270–320 mg iodine  $\cdot \text{ml}^{-1}$  at a rate of  $2\text{--}3 \text{ ml} \cdot \text{s}^{-1}$ <sup>[155,160]</sup>. Streak artifacts, which result from the high concentration of contrast material in the superior vena cava, and which potentially limit the diagnostic accuracy in pulmonary trunk and right pulmonary artery, can be significantly reduced using a low concentration contrast material. Recently, some institutions have adopted a high concentration–high flow approach, where 140–180 ml of contrast medium with 270–300 mg iodine  $\cdot \text{ml}^{-1}$  are administered at  $4\text{--}5 \text{ ml} \cdot \text{s}^{-1}$ .

Image interpretation is usually performed using both soft tissue (mediastinum) and pulmonary parenchymal windows. The side-by-side analysis of images displayed with the two different window settings may be helpful in differentiating pulmonary arteries which accompany the bronchi from venous structures which, in the early phase of scanning, may be unenhanced<sup>[153]</sup>. In addition, cine-mode viewing may provide a dynamic impression of the pulmonary arteries and is generally considered helpful in the analysis of acute PE. Also, the use of two-dimensional multi-planar reformations may aid in the diagnosis of PE<sup>[161]</sup>.

Spiral CT angiography enables the direct visualization of PE within the pulmonary arteries as low attenuation filling defects within the vessel, partly or completely surrounded by opacified blood, or as a complete filling defect which leaves the distal vessel totally unopacified<sup>[153]</sup>. The value of indirect signs of PE, such as pleural-based densities, linear densities or plate-like atelectases, central or peripheral dilatation of pulmonary arteries, and pleural effusions of variable sizes, is less clear<sup>[162]</sup>.

Pitfalls in the interpretation of sCT arteriograms can be attributed to breathing artifacts, which potentially result in a pseudo-hypoattenuating area mimicking a

clot or a non-opacified area in the vessel. On the other hand, prominent perivascular tissue may in some instances be confused with intravascular thromboembolic material and thus mimic PE. In such instances, the use of additional imaging rendering tools such as cine viewing, and multi-planar and three-dimensional image analysis may be helpful<sup>[161,163]</sup>. Eccentrically located, potentially calcified masses within the pulmonary arteries, contiguous with the vessel wall, abrupt cut-off of lobar or segmental arteries, and irregularities of the vessel diameter are considered findings suggestive of chronic PE<sup>[164]</sup>.

The diagnostic accuracy of sCT for PE has been a matter of debate. Initial studies have reported sensitivities and specificities of spiral CT in the evaluation of PE both approaching 100% compared to pulmonary angiography as the gold standard<sup>[153,154]</sup>. However, more recent studies have added more information and somewhat broadened the sensitivity and specificity spectrum of spiral CT angiography with sensitivity ranging from 53% to 89%, and specificity from 78% to 100%<sup>[155,158,165–167]</sup>. The reasons for this apparent heterogeneity seem to be manifold and include differences in study design, investigator experience with sCT, and anatomic extent of the pulmonary vascular tree studied.

Spiral CT provides excellent results for the detection of emboli located in the main, lobar and segmental pulmonary arteries. In cases where emboli are limited to subsegmental and more peripheral arteries, the sensitivity of spiral CT seems to be limited<sup>[160,166]</sup>. In many patients, however, this disadvantage of sCT is counterbalanced by the fact that multiple emboli shower the lung when a large embolus is fragmented in the heart. In one study, an average of more than six emboli were found within the pulmonary arterial system in patients with proven PE<sup>[153]</sup>. The prevalence of isolated subsegmental PE ranges from 6% in the PLOPED population to 17% in patients with a non-diagnostic lung scan result<sup>[85,150]</sup>.

Another factor potentially influencing the accuracy of sCT in the diagnosis of PE is the incidence of PE in the cohort of patients investigated. Indeed, in the first publications the incidence of PE was as high as 57%<sup>[153,158]</sup>. However, a more recent series with an incidence of PE of 23%<sup>[168]</sup> and 33%<sup>[165]</sup> showed similarly good results for sCT.

Finally, should sCT only be compared with pulmonary angiography? Pulmonary angiography has an excellent sensitivity and specificity in the diagnosis of PE, but is not perfect. A recent animal study compared sCT and pulmonary angiography using an independent gold standard (a cast of the porcine vascular tree)<sup>[169]</sup>. No significant differences were found between sCT and angiography, although the numbers were small.

Spiral-CT seems to be a cost-effective method. A cost-effectiveness analysis based on current scientific literature showed that the five strategies with the lowest cost per life saved (and the five strategies with the lowest mortality) all included sCT angiography<sup>[170]</sup>. When cost per life saved was the primary outcome parameter, spiral

CT angiography of the pulmonary arteries and D-dimer tests provided the lowest cost for work-up of patients with suspected PE. With mortality as the primary outcome parameter, a combination of sCT angiography and an ultrasound study of the legs was the best strategy.

Spiral-CT still requires prospective management studies, where the safety of withholding anticoagulant therapy in patients with normal sCT findings needs to be demonstrated. One study followed a cohort of 164 patients with clinically suspected PE, intermediate probability at V/Q scanning, and a negative result at spiral-CT angiography<sup>[171]</sup>. In this study, three out of 164 patients with negative sCT angiography and initially negative results at Duplex ultrasound of the leg veins were found to have clots in the calf veins at short-term follow-up, and were categorized as initially false-negative sCT angiograms. Another three patients experienced recurrent PE during 3 months follow-up (one patient died). Therefore, six out of 112 (5.4%) patients with normal findings at sCT, who did not receive anticoagulant treatment, suffered recurrent events. A second, retrospective study in 260 patients who were followed following normal sCT, in whom anticoagulant therapy was withheld, showed only one recurrent PE<sup>[172]</sup>.

It seems reasonable to assume that sCT deserves a place in the diagnostic algorithm for suspected PE<sup>[173]</sup>. Based on the availability of sCT, the role will increase. In some institutions, sCT has already been incorporated into clinical routine<sup>[174]</sup>. Spiral CT is used as a primary screening test for PE or in combination with lung scintigraphy and ultrasonography. This strategy finds better acceptance among clinicians than a strategy involving pulmonary arteriography.

Finally, spiral CT might be useful for monitoring patients undergoing thrombolytic therapy<sup>[175,176]</sup>. In these patients, CT allows the visualization of embolic material without the need for a central venous puncture, thus reducing the risk of bleeding.

#### Summary

- Spiral CT is more accurate in the demonstration of central or lobar PE than segmental PE.
- A normal sCT does not rule out isolated subsegmental PE.
- The safety of withholding anticoagulant therapy in patients with a normal sCT angiogram needs further confirmation.

#### Echocardiography

Recent large clinical registries including patients with PE showed that echocardiographic data were available in as many as 47%–74%<sup>[4,177]</sup>. The non-invasive character and high emergence availability of this test in many clinical

centres underscores the need for its optimal use and interpretation in patients with suspected or confirmed PE.

Echocardiography might be useful for the differential diagnosis of acute dyspnoea, chest pain, cardiovascular collapse and many other clinical situations that require pulmonary embolism to be considered as a potential diagnosis. This is due to the established diagnostic value of this test in myocardial infarction, infective endocarditis, aortic dissection, pericardial tamponade and others. Moreover, echocardiography may suggest or reinforce clinical suspicion of PE if right ventricular (RV) overload and dysfunction is found in the presence of Doppler signs of increased pulmonary arterial pressure. A typical echocardiographic picture of haemodynamically significant PE includes dilated, hypokinetic RV, an increased RV/LV ratio caused by interventricular septal bulging into the LV, dilated proximal pulmonary arteries, increased velocity of the jet of tricuspid regurgitation (usually in the range of 3–3.5 m . s<sup>-1</sup>), and disturbed flow velocity pattern in the RV outflow tract. Furthermore, the inferior vena cava is usually dilated and does not collapse on inspiration. In 132 patients with suspected PE and without known previous severe cardiorespiratory disease, a combination of right-over-left ventricular diameter ratio greater than 0.5 and Doppler-derived tricuspid regurgitant flow peak velocity greater than 2.5 m . s<sup>-1</sup> was found 93% sensitive but only 81% specific for diagnosis of PE. Echocardiography determined an alternative diagnosis in 55 patients<sup>[178]</sup>.

Recently, RV regional systolic wall motion abnormalities were suggested as a more specific diagnostic sign of acute PE. In contrast to other causes of RV systolic overload and for not totally clear reasons, hypokinesis does not affect the apical segment of RV free wall when it is caused by acute PE. This sign was tested prospectively in 85 patients and found to be 77% sensitive and 94% specific for the diagnosis of acute PE, resolving during successful treatment<sup>[179]</sup>. According to another report, a severely disturbed RV ejection pattern (acceleration time <60 ms) in the setting of only moderate elevation of pulmonary arterial systolic pressure, as assessed by trans-tricuspid systolic gradient <60 mmHg, was 98% specific although only 48% sensitive for acute PE among 86 patients with various causes of pulmonary hypertension<sup>[180]</sup>. Further studies are needed to assess the diagnostic value of those new echocardiographic signs.

Presently, echocardiographic and Doppler analysis of right heart dimensions and RV function permits neither definitive confirmation nor exclusion of suspected PE. However, haemodynamically important PE is unlikely in a patient with a normal echocardiogram. Hypokinesis of the RV free wall was described in 90% of patients with perfusion defects exceeding one third of the total lung fields at scintigraphy<sup>[181]</sup>. The decreased collapsibility index of the inferior vena cava, defined as an inspiratory change in the diameter of less than 40% of its maximum expiratory value, was reported in 82% of 60 patients with clinically important PE. This was also the first echocardiographic sign to improve with treatment,

suggesting that right atrial pressure decreased below 8 mmHg<sup>[182]</sup>.

Echocardiographic criteria, which may distinguish acute from subacute PE, have been suggested<sup>[183]</sup>. The use of predefined indices such as RV free wall thickness >5 mm; tricuspid regurgitant jet velocity >3.7 m . s<sup>-1</sup>; the occurrence of both a dilated RV cavity with normal interventricular septal motion, or an inspiratory collapse of the inferior vena cava correctly identified 11 of 13 patients (85%) with subacute massive PE<sup>[183]</sup>. These criteria require further validation in larger trials.

While echocardiographic signs of RV pressure overload only indirectly support the diagnosis of PE, echocardiography may also definitively confirm this diagnosis by visualization of proximal pulmonary arterial thrombi. Due to the shielding effect of the left main bronchus, the continuity of the left pulmonary artery is usually lost during transoesophageal echocardiographic (TEE) examination. For this reason earlier studies reported mostly on right pulmonary arterial thrombi: in a study of 60 patients with confirmed PE and signs of RV overload, 32 thrombi were located in the right and only six in the left pulmonary artery<sup>[184]</sup>. In a prospective study of 49 patients with unexplained RV overload the distal part of the left pulmonary artery was also evaluated<sup>[183]</sup>. A direct comparison of the diagnostic power of TEE and sCT was performed. While the sensitivity of sCT was higher (97.5% vs 79%) TEE was at least as specific (100% vs 90% for s-CT) and had the advantage of rapid, bedside performance without requiring radiation or contrast injection<sup>[185]</sup>. The sensitivity of TEE in patients with suspected PE but without signs of RV overload is unknown and probably low. However, six out of 14 critically ill patients in whom pulmonary arterial thrombi were accidentally found at TEE had no RV overload at transthoracic echocardiography<sup>[186]</sup>. Bedside TEE may be the first-choice diagnostic test, and may confirm PE, in patients with shock<sup>[187]</sup> or during cardiopulmonary resuscitation<sup>[188]</sup>. Unfortunately, it is not known to what extent the learning curve might affect the sensitivity and — more importantly — the specificity of this test when introduced outside experienced centres.

Echocardiography identified a subgroup of patients with suspected PE, who present with right heart thrombi, usually in-transit from systemic veins to pulmonary arteries. There are several controversies regarding the prevalence, prognostic significance and optimal treatment of such floating thrombi. Recently, the ICOPER registry found right heart thrombi in 4% of 1135 consecutive patients with PE<sup>[4]</sup>. In contrast, in a study in which echocardiography was performed within 24 h from the onset of symptoms their prevalence was as high as 18%<sup>[74]</sup>. Interestingly, this study failed to find any effect of such thrombi on the outcome, provided medical — usually thrombolytic — treatment was promptly introduced. Other series suggested them as markers of high early mortality<sup>[74,189,190]</sup>. Some authors favour surgical removal of these thrombi with concomitant pulmonary embolectomy, due to the perceived risk of dislodgement, which can result in massive PE<sup>[74]</sup>. This

approach seems reasonable when the thrombus is not only blocked in the foramen ovale, but also extends to the left atrium, with impending paradoxical systemic embolism, though successful thrombolysis has also been reported in such cases. Despite those controversies there is a consensus that echocardiographically detected right heart thrombi require immediate treatment. Specifically, right heart catheterization and angiography are contraindicated.

One report suggested that normotensive patients with confirmed PE and subjectively diagnosed RV hypokinesis have worse survival when treated with heparin alone than when initially treated with thrombolysis<sup>[181]</sup>. Early and late mortality was significantly higher in the presence of moderate to severe RV dysfunction assessed with echocardiography in patients with confirmed PE<sup>[4,69]</sup>. Interestingly, short-term prognosis was good in patients with suspected PE, who did not present with signs of RV afterload stress, irrespective of the final diagnosis<sup>[68]</sup>. Because of documented differences in clinical outcome, the Task Force proposes that patients with non-massive PE but presenting right ventricular hypokinesis at echocardiography be classified as submassive PE, to distinguish them from those with normal right ventricular function (who have a better prognosis). There is an urgent need for prospective studies, which assess the role of echocardiography in the identification of patients with PE who may benefit from thrombolytic therapy rather than heparin therapy, despite the absence of systemic hypotension or shock. Recently, pulmonary arterial systolic pressure >50 mmHg as assessed by Doppler echocardiography at the time of diagnosis of PE was found to predict persistence of pulmonary hypertension despite medical therapy<sup>[192]</sup>. The presence of a patent foramen ovale, as assessed by contrast echocardiography, was found to be related to a higher incidence of paradoxical embolism and more marked hypoxaemia among 85 patients who presented with haemodynamically significant PE. Mortality was not significantly higher in these patients than in those without patent foramen ovale (27% vs 19%), however, resuscitation, intubation, or catecholamines were more frequently necessary in the former group (48% vs 23%)<sup>[191]</sup>.

Finally, it is possible to use catheter mounted ultrasound probes for visualization of pulmonary emboli<sup>[193-195]</sup>. This may be helpful in the pre-operative assessment of patients with chronic thromboembolic pulmonary hypertension<sup>[196]</sup>. However, the technique has limited availability and no established clinical role in diagnosis of PE.

#### Summary

- Echocardiography is useful in patients with suspected massive PE.
- Whether echocardiography may identify patients who could benefit from thrombolytic therapy in the absence of systemic hypotension or shock remains to be confirmed in prospective studies.

### Detection of deep vein thrombosis

PE and DVT are different clinical manifestations of a common disease entity, namely VTE. Indeed, autopsy studies have established that PE arises from a lower limb DVT in 90% of patients<sup>[197]</sup>. Moreover, when venography is systematically performed in patients with angiographically confirmed PE, a residual DVT is found in 70% of cases<sup>[148]</sup>. Therefore, the search for a residual DVT in suspected PE patients is rational, since the demonstration of a clot in the lower limbs warrants anticoagulant treatment, rendering further (invasive) diagnostic procedures unnecessary.

Impedance plethysmography (IPG) was very popular in North America, because of its simplicity and low costs<sup>[198]</sup>. Its principle rests on the detection of volume changes of the lower extremity before and after inflation of a cuff applied to the thigh. When the cuff is deflated, the rapidity with which the lower limb volume returns to the baseline is used as an index of venous permeability. IPG was deemed to have a high sensitivity and specificity for symptomatic proximal DVT as compared to venography. More recent data, however, have shown a lower sensitivity (approximately 60%), possibly due to an increase in the frequency of non-occlusive thrombi<sup>[199]</sup>. Moreover, a direct comparison of IPG and compression ultrasonography (US) showed the latter to be more sensitive<sup>[200]</sup>.

Duplex lower limb real-time B-mode compression ultrasonography allows the direct visualization of the femoral and popliteal veins and their compression by the ultrasound probe. Doppler may be helpful to identify the vein, but is not systematically necessary. B-mode US may show the thrombus as a hyperechogenic signal inside the lumen. However, the demonstration of a non-compressible vein is highly specific for DVT and constitutes the only diagnostic criterion<sup>[201,202]</sup>. The sensitivity and specificity of compression US for diagnosing proximal DVT are very high in symptomatic patients, 95 and 98%, respectively<sup>[201]</sup>. However, less favourable results are found for calf vein and asymptomatic DVT.

The majority of patients with PE have no symptoms or signs of DVT<sup>[78,203]</sup>. Nevertheless, the specificity of US in patients with PE remains high (97%)<sup>[82,204]</sup>, as in other categories of asymptomatic patients such as orthopaedic patients screened for venous thromboembolism after hip surgery<sup>[205]</sup>. Several studies have shown that ultrasonography shows a DVT in approximately 30% to 50% of patients with confirmed PE<sup>[83,204,206-210]</sup>. The diagnostic efficacy of US depends on whether it is performed before lung scan, or only in cases of a non-diagnostic lung scan. Indeed, a significant proportion of DVTs in patients with confirmed PE is found in patients with a high probability lung scan, already establishing PE. In the Geneva series, which included emergency ward patients suspected of PE, the diagnostic yield of US was 15% of the entire patient cohort when US was performed before lung scan, vs only 5% if US was done only in the case of a non-diagnostic scan<sup>[207]</sup>.

The corresponding figures in another series, which included both outpatients and inpatients were 13% and 2%, respectively<sup>[204]</sup>. In the most recent series, an initial US also showed a DVT in 5% of the 736 patients with a non-diagnostic scan<sup>[86]</sup>. Finally, combining US to lung scan and angiography is cost-effective and reduces costs by 5 to 15%, provided US is done before lung scan<sup>[211–213]</sup>.

Due to its low sensitivity (30% to 50%) in suspected PE patients, a normal US cannot rule out PE. However, serial US or IPG may allow foregoing angiography in patients with a non-diagnostic scan<sup>[86,214]</sup>. The rationale for serial testing is the following: in a suspected PE patient with a non-diagnostic scan and no DVT in the legs, the thromboembolic risk should be very low, therefore anticoagulant treatment might be withheld. However, US and IPG cannot completely rule out DVT, because these tests are not sensitive for distal (calf-vein) DVT. Nevertheless, the embolic risk associated with isolated distal DVT is low, unless the thrombus extends proximally<sup>[215,216]</sup>. Therefore, serial testing may allow the detection of a proximal thrombus extension, and, thus, identify the patients in whom anticoagulant treatment would be necessary. Two serial testing protocols have been validated in large outcome studies in suspected PE patients<sup>[86,214]</sup>. One strategy used serial IPG in both in- and outpatients, but its application was limited to patients with an adequate cardiorespiratory reserve, and required six IPG examinations over a 14-day period, limiting its clinical usefulness<sup>[214]</sup>. A more recent strategy did not exclude patients with preexisting cardiac or respiratory disease, and is somewhat less resource intensive<sup>[86]</sup>.

#### Summary

- Ultrasonography shows a proximal DVT in 50% of patients with proven PE.
- A normal ultrasonography exam of the leg veins does not rule out PE.
- Serial leg testing may replace angiography in patients with non-diagnostic lung scan findings. However, its practical use seems limited.

### D-dimer

Plasma D-dimer<sup>[217]</sup>, a degradation product of cross-linked fibrin, has been extensively investigated in recent years. D-dimer, when assayed by a quantitative ELISA or ELISA-derived method has been shown highly sensitive (more than 99%) in acute PE or DVT at a cutoff value of  $500 \mu\text{g} \cdot \text{l}^{-1}$ . Hence, a D-dimer level below this value reasonably rules out PE. On the other hand, although D-dimer is very specific for fibrin, the specificity of fibrin for venous thromboembolism is poor. Indeed, fibrin is produced in a wide variety of conditions, such as cancer, inflammation, infection, necrosis. Hence, a D-dimer level above  $500 \mu\text{g} \cdot \text{l}^{-1}$  has

a poor positive predictive value for PE, and cannot reliably rule in the disease. Moreover, specificity of D-dimer is even lower in the very elderly (9% in suspected PE patients older than 80 years<sup>[206,218]</sup>, and inpatients experiencing suspected PE during their hospital stay<sup>[219]</sup>). Hence, D-dimer measurement is unlikely to be useful in such populations.

Table 6 summarizes the performances of various types of D-dimer tests. Traditional latex tests have a low sensitivity and negative predictive value, and should be abandoned. The labour-intensive traditional ELISA tests have been replaced by rapid unitary ELISA-derived assays. Whole blood agglutination tests such as the Simplired<sup>®</sup> have proved disappointing, with a sensitivity of only 85% (95% CI, 83 to 87) in the largest series published to date<sup>[220]</sup>. Very few tests have been validated in clinical large scale outcome studies. D-dimer allowed ruling out PE in 159 of 444 (36%) consecutive patients suspected of PE in the emergency ward, who did not undergo other tests and were not treated by anticoagulants<sup>[83]</sup>. None of these patients had a VTE during 3-month follow-up (0%, 95% CI: 0–2.3%).

#### Summary

- A normal D-dimer level by an ELISA assay may safely exclude PE, provided the assay has been validated in an outcome study.
- Traditional latex and whole agglutination tests have a low sensitivity for PE and should not be used to rule out PE.
- D-dimer is most useful in emergency ward patients. In elderly or inpatients, D-dimer retains a high negative predictive value, but it is normal in less than 10% of patients. and, hence, not very useful.

### Diagnostic strategies

The prevalence of PE in patients in whom the disease is suspected is low (15% to 35% in recent large series)<sup>[83,85,86]</sup>. Pulmonary angiography, the definitive criterion standard is invasive, costly, and sometimes difficult to interpret<sup>[85,228]</sup>. Hence, non-invasive diagnostic approaches are warranted, and various combinations of clinical evaluation, plasma D-dimer measurement, lower limb venous compression ultrasonography (US) and lung scan have been evaluated, to reduce the requirement for pulmonary angiography<sup>[83,86,220]</sup>. These strategies were applied either to patients presenting with suspected PE in the emergency ward<sup>[83]</sup>, during a hospital stay<sup>[229]</sup>, or both<sup>[86]</sup>. Moreover, suspected massive PE is a specific clinical situation, in which a different algorithm should be applied. Finally, it should be recognized that the approach to suspected PE may legitimately vary according to the local availability of tests in specific clinical settings.

**Table 6** Performances of various D-dimer assays in suspected pulmonary embolism

Series	Patients, n	PE, n (%)	Sensitivity, % (95% CI)	Specificity, % (95% CI)
Classical ELISA <sup>*[206,221,222]</sup>	1579	537 (34)	98 (96–99)	43 (40–46)
Rapid ELISA <sup>*[83,223]</sup>	635	152 (24)	100 (98–100)	44 (39–48)
Classical latex tests <sup>[221,222]</sup>	364	167 (46)	92 (88–96)	68 (61–74)
Microlatex (Liatest) <sup>[224,225]</sup>	887	293 (33)	100 (98–100)	40 (36–44)
Whole blood latex test (Simplified <sup>®</sup> ) <sup>[220,226,227]</sup>	1317	232 (18)	87 (82–91)	65 (62–68)

95% CI: 95% confidence interval.

\*Validated in an outcome study.

#### *Suspected PE in the emergency ward*

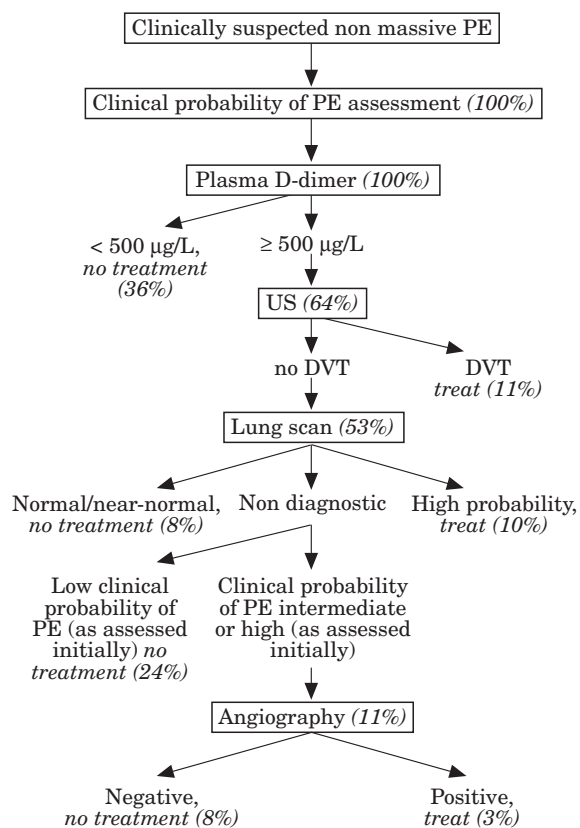
In patients admitted to the emergency ward for suspected PE, a rapid D-dimer assay by the ELISA method is the logical initial test. In a recent series of 444 patients in which the prevalence of PE was 24%, a D-dimer level  $<500 \mu\text{g} \cdot \text{l}^{-1}$  allowed PE to be safely ruled out in 36% of the entire study population<sup>[83]</sup>. These patients did not receive anticoagulant treatment, and none had a venous thromboembolic event during a 3-month follow-up. As already discussed in the corresponding section, the diagnostic yield of venous US is higher when performed before lung scan. Moreover, US is cheaper and more widely available than lung scintigraphy. Hence, performing US as the second test in the sequence is cost-effective<sup>[214]</sup>. In the same study<sup>[83]</sup>, US showed a DVT in 17% of the patients with a D-dimer level  $\geq 500 \mu\text{g} \cdot \text{l}^{-1}$ , i.e. 11% of the entire cohort. Patients with clinically suspected PE and a DVT shown by venous US should receive anticoagulant therapy. Whether such patients should undergo a lung scan that would serve as a baseline exam in the event of a suspected PE recurrence is controversial. Indeed, that situation is infrequent (less than 10% of adequately treated patients), and repeated lung scans are frequently difficult to interpret. Therefore, systematic baseline lung scans are unlikely to be cost-effective. The diagnostic work-up should be pursued in patients with a normal venous US and an abnormal D-dimer level, since 50% of patients with proven PE have a normal US result. Lung scintigraphy is diagnostic (either normal or high probability) in approximately 30% to 50% of emergency ward patients with suspected PE<sup>[84,86,100,215]</sup>. This figure is not significantly influenced by performing D-dimer and US before lung scintigraphy: among the patients with an abnormal D-dimer level and a normal venous US, 16% had a normal/near-normal scan result, and 18% a high probability scan<sup>[83]</sup>. Hence, combining D-dimer, venous US and lung scan allows a definite diagnosis in approximately 65% of outpatients with suspected PE. The number of patients who require angiography may be further reduced by taking clinical probability into account at this stage of the diagnostic work-up. Indeed, patients with a non-diagnostic lung scan, a normal venous US and a low clinical probability of PE have a very low prevalence of PE. In one trial, PE could be ruled out by this constellation in an additional 24% of patients<sup>[83]</sup>. Moreover, in

a recent analysis of a large database of consecutive outpatients suspected of PE, 21% of the patients with such a combination of findings were left untreated, and the 3-month thromboembolic risk was only 1.7%<sup>[84]</sup>. Therefore, combining D-dimer, venous US, lung scan and clinical evaluation allowed diagnosing or ruling out PE in 89% of the study patients, reducing the patients requiring angiography to only 11%<sup>[83]</sup>. Figure 1 summarizes this diagnostic strategy. Any step in the algorithm may be skipped, if the corresponding test is not locally available.

Admittedly, in many centres, lung scintigraphy and/or angiography would be replaced by spiral CT angiography in the diagnostic work-up. However, no large-scale outcome studies assessing that approach are available at present. Most experts would agree that patients in whom sCT shows PE may be treated without further tests. However, the best course of action in the presence of a negative sCT is still controversial. Indeed, in the only series in which patients with a low probability lung scan, a normal venous US, and a normal sCT scan remained untreated, the 3-month thromboembolic risk was unacceptably high (5.4%)<sup>[171]</sup>. Therefore, more data are needed to assign a definite position for sCT in a rational and evidence-based diagnostic strategy for suspected PE.

#### *Suspected PE in hospitalized patients*

Although the incidence of suspected PE in patients staying in the hospital for another medical or surgical problem is lower than in the emergency ward, it remains an important clinical problem. Furthermore, the contribution of some of the non-invasive diagnostic instruments is lower in that patient population. Indeed, due to a high prevalence of conditions other than VTE yielding an elevated D-dimer level (infection, cancer, inflammation, etc.), this test will allow PE to be ruled out in less than 10%<sup>[221,222,229]</sup>. Similarly, clinical evaluation is less often useful, since the vast majority of patients who have been operated on have at least an intermediate clinical probability of PE. In a study evaluating a combination of tests similar to that detailed in Fig. 1 in hospitalized patients, 36% of the patients required an angiogram, compared to only 11% in emergency ward patients<sup>[229]</sup>. Clearly, hospitalized patients with suspected PE would greatly benefit from the replacement of angiography by sCT. However, insufficient data are available to forego



**Figure 1** Proposed diagnostic algorithm for non-massive suspected pulmonary embolism in emergency room patients. Numbers between parentheses represent the proportion of patients at each stage of the algorithm, from a trial performed in emergency ward patients (adapted from ref.<sup>[18,31]</sup>). Note that plasma D-dimer measurement is of limited usefulness in suspected PE occurring in hospitalized patients. Moreover, any step can be omitted from the diagnostic work-up in cases of non-availability of the corresponding diagnostic test, except pulmonary angiography. Helical CT scan may replace lung scan and/or angiography in some centres (see text for comments). PE=pulmonary embolism; US=lower limb venous ultrasonography; DVT=deep vein thrombosis.

angiography in hospitalized patients with suspected PE, a normal venous US, a non-diagnostic lung scan and a normal sCT.

Another diagnostic algorithm which uses lung scintigraphy, clinical evaluation and serial US has recently been validated in both inpatients and outpatients<sup>[86]</sup>. In that series, patients with a low or moderate clinical probability of PE, as assessed by a prediction rule, underwent a venous US on day 1, which showed a DVT in 3%. The remaining patients were managed by a serial US protocol (US on days 3, 7, and 14), which diagnosed a DVT in an additional 2% of patients. Patients in whom serial US did not show a DVT were left untreated, and the 3-month thromboembolic risk was very low (0.5%). However, the prevalence of PE was very low in this series, the prediction rule for assessing clinical probability was complex, and 95% of the patients with a low

or moderate clinical probability and a non-diagnostic scan required the resource intensive serial US protocol. Although, this clearly limits the clinical usefulness of that approach, it might be an alternative in hospitalized patients in whom clinicians are reluctant to perform an angiogram.

#### *Suspected massive PE*

Patients suspected of massive PE, i.e. presenting with shock, or hypotension, represent a distinct clinical problem. The clinical suspicion is usually high, and the differential diagnosis includes cardiogenic shock, tamponade and aortic dissection. Hence, the most useful initial test in that situation is echocardiography, which will usually show indirect signs of acute pulmonary hypertension and right ventricular overload if acute PE is the cause of the haemodynamic consequences. In a highly unstable patient, thrombolytic treatment (or even surgery) for PE may be undertaken based on compatible echocardiographic findings alone. If the patient is stabilized by supportive treatment, a definite diagnosis should be sought. Due to the high thrombus load in the pulmonary circulation, both lung scan, sCT and bedside TEE are usually able to confirm the diagnosis. Case reports of patients with massive PE and a normal lung scan result have been published, but should be considered anecdotal. Hence, a normal lung scan or sCT angiogram should prompt the search for another cause of shock.

## Treatment

### *Haemodynamic and respiratory support*

Acute circulatory failure is the leading cause of death in patients with acute massive PE and is primarily caused by a reduced cross-sectional area of the pulmonary vascular bed and by pre-existing cardiac or pulmonary disease<sup>[230,231]</sup>. When present in patients with acute PE, acute circulatory failure is mainly due to RV ischaemia and LV diastolic dysfunction, which ultimately leads to LV failure.

The increase in RV afterload leads to an increase in RV work and oxygen consumption. Systemic hypotension or elevated mean RV pressure may reduce RV coronary perfusion pressure and myocardial blood flow<sup>[232]</sup>. The resulting RV ischaemia has been confirmed in patients with acute massive PE by an increase in creatinine kinase MB isoenzyme, or even right ventricular infarction at autopsy despite normal coronary arteries<sup>[233,234]</sup>.

RV failure results in reduced LV preload whereas the increase in RV-end-diastolic pressure reverses the diastolic trans-septal pressure gradient resulting in diastolic ventricular interdependence and decreased LV end-diastolic volume which is further constrained by the increased pericardial pressure<sup>[235]</sup>. The resulting

impaired LV diastolic function contributes to the low cardiac index and systemic hypotension, and thereby further worsens RV ischaemia.

A significant number of the deaths caused by massive PE occur within the hours after the onset of symptoms. Initial supportive treatment could therefore have a major role in patients with PE and circulatory failure. However, most of our knowledge on the effectiveness of this treatment arises from experimental studies with questionable significance as regards clinical practice.

Most experimental studies indicate that fluid loading further deteriorates the haemodynamic status of animals with PE and hypotension<sup>[236]</sup>. Only two clinical studies have addressed this issue. Ozier *et al.* reported an increase in cardiac index from 1.7 to 2.0 l · mn<sup>-1</sup> · m<sup>-2</sup> after 600 ml fluid loading in 13 patients with PE, half of them being mechanically ventilated<sup>[237]</sup>. More recently, Mercat *et al.* observed an increase in cardiac index from 1.6 to 2.0 l · mn<sup>-1</sup> · m<sup>-2</sup> after a 500 ml dextran 40 infusion in 13 normotensive patients with acute PE and low cardiac index. In the latter study, there was an inverse correlation between the increase in cardiac index and RV end-diastolic volume index<sup>[238]</sup>. All in all, these results suggest that a 500 ml fluid challenge may result in a significant albeit modest increase in cardiac index in patients with PE, low cardiac index and normal blood pressure. However, available data in humans suggest that the benefit is even slighter in cases of frank RV distension and animal experiments even suggest that this treatment may be harmful when systemic hypotension is present.

Isoproterenol is an inotropic drug, which produces PA vasodilatation, but its use is limited by tachycardia and systemic vasodilatation. In dogs with shock and hypotension produced by PE, isoproterenol did not reverse systemic hypotension<sup>[232]</sup>. One case report further suggests that isoproterenol may be deleterious in patients with PE and shock<sup>[239]</sup>. Norepinephrine can reverse hypotension and shock and increase the cardiac output in hypotensive animals with PE<sup>[232]</sup>, whereas this was not seen in animals with PE, normal blood pressure and low cardiac output<sup>[240]</sup>. No clinical data are available on the effect of this drug in PE patients, and its use should probably be limited to hypotensive patients.

Dobutamine and dopamine both increase cardiac output and decrease pulmonary vascular resistances (PVR) in dogs with experimental PE<sup>[241]</sup>. In 10 patients with PE, low cardiac index and normal blood pressure, Jardin *et al.* observed a 35% increase in cardiac index without a significant change in heart rate, systemic arterial pressure and mean PAP<sup>[242]</sup>. The same group of investigators observed a 57% increase in cardiac output, a 12% increase in heart rate and a 53% increase in PAP in 13 other patients<sup>[242]</sup>. According to these results, both dobutamine and dopamine may be used in patients with PE, low cardiac index and normal blood pressure.

Epinephrine has not been investigated in experimental PE studies, but a case report suggest a beneficial effect of this drug in patients with PE and shock<sup>[243]</sup>. Experimental studies suggest a role for vasoconstriction in PE<sup>[244]</sup>

but this phenomenon is probably limited in patients with PE.

Although vasodilators decrease PAP and PVR in animals and to a lesser extent in PE patients, they also decrease systemic arterial pressure limiting their clinical use<sup>[244,245]</sup>. More recently, inhaled nitric oxide (NO) was shown to selectively decrease PAP and PVR in piglets with experimental pulmonary hypertension induced by microspheres infusion<sup>[246]</sup>. It has also been shown in a few patients that inhalation of NO may improve the haemodynamic status and gas exchange in patients with PE<sup>[247]</sup>.

Hypoxaemia and hypocapnia are commonly encountered in patients with PE but hypoxaemia is moderate in most patients. Only 30 of 160 patients of the UPET study received oxygen and P<sub>a</sub>O<sub>2</sub> was below 80 mmHg in 89% of the 130 patients without oxygen<sup>[248]</sup>. In the same study, only 16% of the patients who did not receive oxygen had P<sub>a</sub>O<sub>2</sub> above 50 mmHg. Hypoxaemia is usually reversed with nasal oxygen and mechanical ventilation is rarely necessary<sup>[249]</sup>. When mechanical ventilation is required, care should be given to limit its haemodynamic adverse effects. Positive intrathoracic pressures induced by mechanical ventilation reduce the venous return and worsen RV failure in patients with massive PE. Accordingly, some authors use low tidal volumes (7 ml · kg<sup>-1</sup>) and advocate fluid loading.

#### Summary

- Dobutamine and dopamine may be used in patients with PE, low cardiac index and normal blood pressure.
- Vasopressive drugs may be used in hypotensive patients with PE.
- Monitored oxygen therapy is beneficial in patients with PE and hypoxaemia.
- The usefulness of fluid challenge is controversial and should not exceed 500 ml.

#### Thrombolytic treatment

The increase in RV afterload observed in patients with massive PE may induce RV failure, systemic hypotension and shock, all associated with a poor outcome<sup>[68,250–252]</sup>. Thrombolytic therapy has beneficial effects on these parameters. In patients with pulmonary hypertension and low cardiac output due to PE, thrombolytic therapy induces a 30% reduction in mean PAP and a 15% increase in cardiac index 2 h after treatment institution<sup>[253]</sup>; at 72 h, a 80% increase in cardiac index and a 40% decrease in PAP have been observed<sup>[254]</sup>. A significant reduction in mean RV end-diastolic area has also been recorded 3 h after treatment<sup>[251]</sup>. In the same studies, heparin alone did not produce any change in cardiac index, pulmonary artery pressure or echographic findings at 2 or at 72 h after the beginning of therapy.

**Table 7** Contraindication to fibrinolytic therapy in patients with massive PE*Absolute contraindications*

- Active internal bleeding
- Recent spontaneous intracranial bleeding

*Relative contraindications*

- Major surgery, delivery, organ biopsy or puncture of non-compressible vessels within 10 days
- Ischaemic stroke within 2 months
- Gastrointestinal bleeding within 10 days
- Serious trauma within 15 days
- Neurosurgery or ophthalmologic surgery within 1 month
- Uncontrolled severe hypertension (systolic pressure >180 mmHg; diastolic pressure >110 mmHg)
- Recent cardiorespiratory resuscitation
- Platelet count <100 000/mm<sup>3</sup>, prothrombin time less than 50%
- Pregnancy
- Bacterial endocarditis
- Diabetic haemorrhage retinopathy

Thrombolytic treatment also produces a faster reduction in pulmonary vascular obstruction as compared to heparin alone. In the PAIMS 2 study, 100 mg of recombinant tissue plasminogen activator (rtPA) induced a 12% decrease in vascular obstruction at the end of the 2 h infusion time, whereas no change was observed in patients who were receiving heparin. At 24 h, a 35% reduction has been observed after rtPA, whereas the corresponding figure was only 5% with heparin<sup>[251]</sup>. However, on the 7th day, the decrease in vascular obstruction was similar in both groups<sup>[248,253]</sup>.

Thrombolytic therapy also carries hazards. Severe bleeding occurs in 14% of the patients with PE who are receiving thrombolytic therapy after pulmonary angiography<sup>[255,256]</sup>, which is twice the rate observed in heparin treated patients<sup>[257]</sup>. Bleeding at the venous puncture site for angiography represents the first source of bleeding and accounts for 36 to 45% of major haemorrhages<sup>[248,258]</sup>. Intracranial bleeding occurs in 1.9% in these patients<sup>[259]</sup>. Data on bleeding complications in patients receiving thrombolytic therapy for PE diagnosed by non-invasive tests are limited, but two studies reported no major bleeding<sup>[251,259]</sup>.

The outcome was assessed in only 431 patients in eight randomized studies, which compared heparin and thrombolysis in patients with PE<sup>[248,251,253,254,260–263]</sup>. Most patients included in seven of these studies did not have massive PE. In these studies, the mortality in the heparin group varied from 0 to 18% and no survival advantage of thrombolysis over heparin was found. However, none of these studies had sufficient power to detect potentially important differences between the two treatment regimes. The last randomized study included only eight patients with massive PE and cardiogenic shock, four have been allocated to heparin and died as a result of pulmonary embolism, whereas the four who received thrombolysis survived; this difference in outcome was highly significant and the study was interrupted for ethical reasons<sup>[263]</sup>.

In patients with PE and evidence of RV afterload, the use of thrombolytic treatment is independently associated with survival (Odds Ratio : 0.46 ; 95% CI: 0.21–1.00) but this result arises from an observational

uncontrolled study<sup>[252]</sup>. There is some indirect evidence that thrombolysis may reduce mortality in patients with RV hypokinesia but this was the result of a subgroup analysis on a limited number of patients<sup>[251]</sup>.

Several thrombolytic drugs have been applied in clinical studies<sup>[248,251,253,254,260–273]</sup>. Although no difference in mortality was found between the different regimen of rtPA, streptokinase or urokinase evaluated in controlled studies, several differences do exist as regards early haemodynamic efficacy and safety. The currently available data indicates that a 2-h 100 mg infusion of rtPA acts more rapidly than urokinase given as a 4400 IU . kg<sup>-1</sup> . h<sup>-1</sup> dose during 12 to 24 h<sup>[264,265]</sup>. This regimen also produces a faster haemodynamic improvement as compared to a 0.6 mg . kg<sup>-1</sup> 15 min rtPA infusion or a 1.5 million IU dose of streptokinase delivered over 2 h, although the difference between these three regimens is limited to the first hour<sup>[266–268]</sup>.

The rate of major bleeding cannot be compared between studies using different bleeding assessment scores<sup>[258]</sup>. Using the same definition, two studies observed major bleeding in 28% of patients receiving urokinase as a 4400 IU . kg<sup>-1</sup> . h<sup>-1</sup> dose over 12 h, in 21% to 24% of those treated by the 2 h 100 mg rtPA regimen and in 11% of patients receiving 0.6 mg . kg<sup>-1</sup> of rtPA given over 15 min<sup>[265,266]</sup>. However, none of these differences was statistically significant as a result of the limited number of patients included in those studies.

Several contraindications exist for thrombolytic therapy. In a patient with massive PE most of these are considered only relative contraindications (Table 7).

Based on the available data, there is a survival benefit from thrombolytic therapy in patients with massive PE, i.e. those with shock and/or hypotension (defined as a systolic blood pressure <90 mmHg or a pressure drop of ≥40 mmHg for >15 min if not caused by new-onset arrhythmia, hypovolaemia or sepsis).

In patients with normal blood pressure and clinical, haemodynamic or echocardiographic evidence of RV failure (submassive PE), the benefit is less clear and has not been established or ruled out in adequate randomized studies. When vascular obstruction is less than 50% and in patients with neither massive nor

submassive PE, mortality is less than 5% in the most recent studies<sup>[269,270]</sup> and any benefit of thrombolysis in these patients is very unlikely. Finally, the choice of the drug is not a major issue, although the faster haemodynamic effect of the 2 h 100 mg infusion of rtPA may be relevant in the sickest patients, whereas the low incidence of bleeding observed with the 0.6 mg · kg<sup>-1</sup> rtPA bolus injection may be of value in patients with relative contraindications.

Unless absolutely contraindicated, thrombolysis should be given to all patients with massive PE. In patients with normal blood pressure, normal tissue perfusion and clinical or echocardiographic evidence of RV dysfunction (i.e. submassive PE), thrombolytic therapy may be given in the absence of contraindications. Thrombolytic therapy should not be given in patients with neither massive nor submassive PE unless they have haemodynamic impairment due to previous cardiac or pulmonary disease.

When to start thrombolytic treatment? Angiographic confirmation is no longer warranted in all patients subjected to thrombolysis. It is time consuming, not without hazards in these patients<sup>[265]</sup> and is associated with an increase in bleeding complications<sup>[258]</sup>. A diagnostic perfusion lung scan coinciding with a high clinical probability<sup>[91]</sup>, proximal obstruction on sCT<sup>[153]</sup> or evidence of acute cor pulmonale coinciding with a high clinical suspicion in patients without major previous cardiac or respiratory disease all allow a sufficient level of proof to start thrombolytic therapy if required.

#### Summary

- Thrombolytic therapy is indicated in patients with massive PE, as shown by shock and/or hypotension.
- Most contraindications for thrombolytic therapy in massive PE are relative.
- Thrombolytic therapy should be based on objective diagnostic tests.
- The use of thrombolytic therapy in patients with sub-massive PE (RV hypokinesia) is controversial.
- Thrombolytic therapy is not indicated in patients without right ventricular overload.

#### Surgical embolectomy

Although there are no randomized trials demonstrating improved survival with thrombolytic therapy in PE, this treatment is generally believed to be an effective therapeutic strategy, and nowadays surgery is rarely performed. Nevertheless, there remains a limited role for surgical treatment of PE.

In the pre-echocardiography era, diagnosis of massive PE was usually made by angiography, and this examination was considered mandatory before any surgical procedures<sup>[272]</sup>. The angiography provided the vital information necessary for planning the procedure, such

as confirmation of diagnosis, size and location of PE and RV function. Currently this information is available with TEE in most cases with massive PE<sup>[185,187,275]</sup>.

Indications for surgery currently consist of three patient categories<sup>[276-278]</sup>: patients with acute, massive PE; patients with contraindications to thrombolytic treatment; and patients who lack a response to intensive medical treatment and thrombolysis.

The optimal surgical candidate is a patient with subtotal obstruction of the main pulmonary artery or its major branches, without fixed pulmonary hypertension. The latter usually indicates a chronic thromboembolic obstruction, and emergency surgical treatment cannot relieve the obstructions in distal pulmonary artery branches. Although there is limited evidence to suggest that some patients in shock might survive with thrombolytic therapy alone, the decision regarding operation must be made on a case-by-case basis.

The surgical technique consists of median sternotomy, with rapid cannulation of the ascending aorta and right atrium and institution of normothermic cardiopulmonary bypass<sup>[279]</sup>. Aortic cross clamping is avoided. The emboli are removed via a longitudinal incision in the main pulmonary artery, using common bile duct forceps or malleable non-occlusive grasping instruments<sup>[280]</sup>. A standard sucker is used to extract the most distal clots.

Normothermic bypass offers several advantages. It provides excellent resuscitation in cardiogenic shock, restoring blood flow and oxygen delivery to the tissues. It also gives the surgeon ample time to perform a complete embolectomy and to explore side branches of the pulmonary artery. Furthermore, cardiopulmonary bypass can function as a circulatory assistance, because a dilated, acutely failing right ventricle will need some pharmacological and mechanical support after completion of the embolectomy. In patients under ongoing resuscitation, cardiopulmonary bypass can be instituted by cannulation of femoral vessels or with percutaneous cardiopulmonary support, thus providing oxygenated blood to vital organs<sup>[281]</sup>. This technique can also be helpful if the systemic artery pressure falls under the critical value required during induction of anaesthesia.

Some experts feel that pulmonary embolectomy should be combined with vena cava filter insertion<sup>[282,283]</sup>. With the newer retrievable filters, one may consider removal if venography after 10–14 days reveals no distal thrombi. However, if no DVT is present at the time of surgery and there are no contraindications for anticoagulation, filter insertion is controversial.

The main goal of the surgical procedure is to prevent death from major pulmonary artery obstruction, causing acute right heart failure and preventing blood flow through the lungs. Results of surgical pulmonary embolectomy are poor, because it is usually performed in moribund patients, often following prolonged resuscitation<sup>[279,284,285]</sup>. Operative mortality for embolectomy ranges from 20–50%. Operative mortality is determined by resuscitation prior to surgery; age; duration of symptoms; and number of episodes of PE. Long-term survival rate is acceptable, with 71% surviving after 8 years

**Table 8** Weight-based nomogram from Raschke et al.<sup>[291]</sup>

Initial dose	80 U . kg <sup>-1</sup> bolus, then 18 U . kg <sup>-1</sup> h <sup>-1</sup>
aPTT <35 s (<1.2 × mean normal)	80 U . kg <sup>-1</sup> bolus, then increase infusion rate by 4 U . kg <sup>-1</sup> h <sup>-1</sup>
aPTT, 35 to 45 s (1.2 to 1.5 × mean normal)	40 U . kg <sup>-1</sup> bolus, then increase infusion rate by 2 U . kg <sup>-1</sup> h <sup>-1</sup>
aPTT, 46 to 70 s (1.5 to 2.3 × mean normal)	No change
aPTT, 71 to 90 s (2.3 to 3.0 × mean normal)	Decrease infusion rate by 2 U . kg <sup>-1</sup> h <sup>-1</sup>
aPTT >90 s (3 × mean normal)	Stop infusion 1 h, then decrease infusion rate by 3 U . kg <sup>-1</sup> h <sup>-1</sup>

aPTT=activated partial thromboplastin time.

(operative mortality of 20%). There is also a major improvement in functional status of the operated patients, with 84% in NYHA I and II after 8 years

Percutaneous catheter embolectomy or catheter disruption of thrombi offers alternatives for patients who do not require cardiopulmonary resuscitation. Percutaneous endoluminal methods are difficult to initiate and their clinical use has been limited<sup>[286–288]</sup>.

#### Summary

- Acute pulmonary thrombectomy has a limited role in massive, life-threatening PE.
- If confirmation of massive central PE prior to surgery can be obtained by echocardiography (preferably TEE) or sCT, angiography is not systematically required.

### Anticoagulant therapy

Unfractionated heparin (UFH) treatment in PE is well established since the classic clinical trial performed by Barritt and Jordan in 1960<sup>[66]</sup>. At the recent Vth North American Consensus Conference on Thrombosis and Antithrombotic agents in April 1998<sup>[289]</sup>, the recommendation was that patients with DVT or PE should be treated with a dose of heparin sufficient to prolong the activated partial thromboplastin time (aPTT) to a range corresponding to a plasma heparin level of 0.30–0.60 anti-Xa IU as determined with an amidolytic assay<sup>[269,270,289]</sup>. Low molecular weight heparin (LMWH) can be substituted for UFH in the treatment of stable patients with PE<sup>[269,270]</sup>, but cannot be recommended for massive PE, as such patients were excluded from the trials on PE treatment by LMWH.

An accurate diagnosis of PE is essential before prescribing prolonged anticoagulant treatment. However, heparin should be administered while awaiting a definitive diagnosis, at least in patients with an intermediate or high clinical probability of PE. Initial therapy with oral anticoagulant alone may be less effective or even dangerous<sup>[290]</sup>. Thus, heparin (UFH and possibly LMWH) is the cornerstone of the initial management of acute PE. Finally, contraindications to anticoagulant therapy, such as active bleeding, haemostatic disorders, severe uncontrolled hypertension and recent surgery should be considered in

selecting anticoagulant treatment. However, most of these are relative contraindications in patients with proven PE.

The initial therapy consists of intensive anticoagulation with heparin, i.e. an i.v. bolus of UFH (usually 5000 to 10 000 IU) followed by a continuous i.v. infusion. The infusion rate can be adapted to body weight according to existing nomograms<sup>[291]</sup> (Table 8), but should not be lower than 1250 IU . h<sup>-1</sup>. Higher starting infusion rates have been shown to result in faster achievement of a therapeutic anticoagulant level<sup>[292]</sup>, but the evidence for a higher rate of recurrence in patients with a subtherapeutic anticoagulation level is inconclusive, provided the infusion rate is higher than 1250 IU . h<sup>-1</sup>. The infusion rate should be adapted to the level of anticoagulation ascertained by the aPTT (target aPTT:aPTT ratio patient/control 1.5 to 2.5). The first aPTT should be measured 4 to 6 h after initiation of the heparin infusion. Due to the variability of aPTT results with different reagents, it is recommended that each laboratory should determine the range of aPTT ratio with the reagent used. This should correspond to an anti-Xa activity ranging from 0.3 to 0.6 IU with an amidolytic method (these values correspond to the range 0.20–0.40 IU with the protamine sulfate test)<sup>[289]</sup>. In special circumstances, such as resistance of the aPTT ratio response to recommended dose of heparin, anti-Xa measurement may be required<sup>[293]</sup>. In this special group of patients, it has been shown that this phenomenon could be related to an increased binding of heparin to different plasma proteins, the level of which could be increased in some patients<sup>[294]</sup>. Another possibility could be the substitution of a LMWH preparation, since these agents have less propensity to bind to plasma proteins.

The existence of an association between prolonged aPTT and bleeding is generally accepted. However, all the experts have recognized that bleeding during heparin therapy is infrequent unless some invasive procedure is performed or the patient has a local lesion or haemostatic abnormalities. The same applies to LMWH. The studies on the relationship between excessive prolongation of aPTT levels and bleeding complications are less conclusive<sup>[295,296]</sup>. However, it is likely that a relationship exists.

Monitoring platelet count is important since heparin induced thrombocytopenia (HIT) is a rare, but life threatening side effect. Two forms of HIT have been described: an early benign form, which is reversible during treatment, due to a non-immune mechanism. The

second one is paradoxically associated with venous and arterial thrombotic complications and usually occurs between 5–15 days of treatment. A sudden unexplained decrease in platelet count below  $100 \times 10^9 \cdot l^{-1}$  or a pronounced decrease  $>30\%$  are important warning signals. Discontinuation of heparin results in a progressive increase in platelet count in less than 10 days. Platelet count should be monitored every second day during treatment.

The frequency of HIT is greater with UFH than with LMWH<sup>[297]</sup>. In the prophylactic treatment of patients with total hip replacement, the frequency of HIT was about 1%. The diagnosis of HIT is difficult because there are no gold standard criteria or routine laboratory tests. The reference test is based on serotonin release. The Fratantoni test is a platelet aggregation test, which requires very well defined standardization. More recently, an ELISA test has been made available, which detects heparin antibodies directed against platelet factor 4-heparin complexes. Although it does not replace the other tests mentioned, it is becoming an important complementary test. The concordance between platelet aggregation tests and the newly developed ELISA test is only approximately 80% for various reasons.

The safety and efficacy of low molecular weight heparin (LMWH) for the treatment of non-massive PE was compared with UFH in two recent large, controlled, randomized studies<sup>[269,270]</sup>. Tinzaparin (single daily s.c. injection) was proven as effective and safe as UFH in 612 patients<sup>[269]</sup>. In the COLUMBUS study among 1021 patients with proven VTE, 271 had symptomatic PE at presentation<sup>[270]</sup>. These patients were treated either with reviparin (2 s.c. injections/day) or with conventional UFH. There was no difference between both treatments regarding the VTE recurrence rate, bleeding and mortality.

The use of LMWH may shorten hospital stay and improve quality of life for patients. It is essential to use the dosage which was used in these trials. Thus, tinzaparin is given at a dose of  $175 \text{ anti-Xa} \cdot \text{kg}^{-1}$  once daily, while reviparin was used at a dose of  $85 \text{ anti-Xa IU} \cdot \text{kg}^{-1}$  twice a day by subcutaneous route. It is not recommended to extrapolate the dose from one LMWH preparation to another. However, since tinzaparin and reviparin have widely different anti-Xa/anti-IIa activity ratios, it is probably safe to treat PE with other LMWHs, provided their efficacy and safety has been demonstrated in the treatment of DVT, and local regulations allow their use for such treatment. Laboratory monitoring is not required except for a regular platelet count before treatment initiation and on the 5th day, then every 2 to 3 days if heparin treatment is continued. Since renal clearance of LMWH is important, the monitoring of anti-Xa activity in elderly patients and those with chronic renal failure has been advocated, but this remains controversial. Although recent studies have shown that subcutaneous therapy with LMWH in the home environment was efficacious and safe in selected patients with DVT<sup>[298–301]</sup>, ambulatory treatment of PE cannot yet be recommended, pending further clinical

trials. Finally, due to lack of evidence, LMWHs cannot be recommended for the treatment of massive PE.

If PE occurs postoperatively, heparin therapy should not be started until 12–24 h after major surgery. Treatment could be delayed even longer if there is any evidence of bleeding from the surgical site<sup>[302]</sup>. Heparin should be started without a bolus and at a dose moderately lower than the conventional dose. The aPTT should be checked 4 h after initiation of the treatment. A rigorous surveillance of the surgical site and clinical supervision of the patient is required. (Temporary) vena cava filter placement should be considered if patients have a very high risk of bleeding.

Heparin may be administered during pregnancy. It does not cross the placenta and is not dangerous for the fetus. During pregnancy a resistance to heparin is relatively common and an increase in the dosage should be considered. Subcutaneous UFH is usually used after the initial phase of treatment with i.v. infusion. The dose is adjusted according to aPTT or, in some cases, according to anti-Xa<sup>[38]</sup>. The heparin treatment in pregnant women with PE should be prolonged until at least 6 weeks after delivery. Subcutaneous UFH is given twice a day and monitored by the aPTT, blood being collected 6 h after the subcutaneous injection. LMWHs have been used in pregnant women with DVT but limited information about their use in PE is available<sup>[303]</sup>. After delivery, a switch to oral anticoagulant is considered even in breast feeding mothers since the oral anticoagulant is not found in the milk, especially when warfarin is used. Long-term heparin treatment is associated with a risk of early osteoporosis.

The rate of recurrent VTE is increased in cancer patients, which may indicate long-term treatment. LMWH may be used at the same dose as in patients with DVT. Although no clear recommendations exist, anti-Xa measurement should be considered. Some authors consider that heparins are more effective than oral anticoagulants in the secondary prevention of VTE in cancer patients. Long-term LMWH therapy has been suggested for patients with metastatic cancer, because oral anticoagulation alone may fail to prevent recurrent VTE<sup>[304]</sup>.

The management of thrombosis in patients with an antiphospholipid (APL) syndrome may be complicated, since the APL syndrome is often associated with circulating anticoagulant, which prolongs aPTT. Anti-Xa measurement seems preferable to aPTT for the laboratory monitoring of these patients since the circulating anticoagulant will not influence anti-Xa measurement with an amidolytic method<sup>[305,306]</sup>.

The use of UFH and LMWH is contraindicated in patients with HIT and starting oral anticoagulants without another immediately active anticoagulant may be hazardous<sup>[307,308]</sup>. Various treatments have been used in these patients. They include danaparoid sodium (a heparinoid preparation, containing mainly heparan sulphate and dermatan sulphate), r-hirudin and argatroban, a chemical anti-thrombotic agent<sup>[309,310]</sup>. The use of r-hirudin is restricted to patients with HIT associated

with a new thrombotic episode or an aggravation of PE. Its monitoring requires repeated aPTT measurement. The same applies to danaparoid sodium, which has a long half-life and potential cumulative effect. The dose recommended is 750 anti-Xa IU twice a day, given subcutaneously. An intravenous route can also be used in some patients. Anti-Xa measurement is commonly used for patients monitoring.

The oral anticoagulants in current use in Europe are sodium warfarin, acenocoumarol and fluindione (warfarin being the predominant derivative in clinical use). They are well absorbed in the gut and transported in plasma highly bound to albumin (97%–99%). The drugs are metabolized in the liver and excreted in a hydroxylated form in the urine. The plasma half-life is about 42 h for warfarin, 9 h for acenocoumarol and 31 h for fluindione. This half-life is important, as longer half-life is correlated with less fluctuation in the level of anticoagulation. The oral anticoagulants inhibit the synthesis of four vitamin K dependent coagulant proteins (factors II, VII, IX, X) in the liver and limit the carboxylation of proteins C and S (anticoagulant proteins) which decrease their activity<sup>[311]</sup>.

Patients who require long-term anticoagulant therapy need to be switched from heparin to oral management. It is recommended in most patients to initiate OAT on the first or second day of heparin treatment. The start of coumarin therapy should be with the expected maintenance dose, which is 5 mg daily for warfarin, 3 mg daily for acenocoumarol and 20 mg daily for fluindione. Adjustment of dose depends on INR monitoring. A loading dose of oral anticoagulants is not useful to obtain an INR in the therapeutic range (2.0–3.0) more rapidly than maintenance dose<sup>[312]</sup>. This may even be harmful by inducing a temporary hypercoagulable state due to the shorter half-life of proteins C and S compared to other coagulation factors (II, VII, IX, X). Therefore, concomitant heparin treatment must be continued for 4–5 days until a therapeutic range of INR has been obtained for at least 2 consecutive days<sup>[290,313,314]</sup>.

INR monitoring is usually performed daily until the therapeutic range has been achieved, then twice or three times weekly during the first 2 weeks and then once a week or less often depending of the stability of the INR results<sup>[311]</sup>. During long-term treatment, frequency of controls can be reduced to intervals as long as every 4 weeks.

The intensity of anticoagulation may be adjusted according to the clinical setting. Evidence from many studies indicates that effective therapy in VTE is obtained with an INR value between 2.0 to 3.0<sup>[269,270,315]</sup>. When INR is between 3.0 and 4.5, the incidence of VTE recurrence was not decreased but bleeding complications occurred four times more frequently<sup>[315]</sup>.

The duration of anticoagulation is dependent on the type of event and the coexistence of prolonged risk factors. The risk of recurrence of VTE is less in patients with a temporary or reversible risk (e.g. thrombosis

secondary to surgery or trauma) than it is in those with continuing risk factor (e.g. malignancy) or with idiopathic VTE<sup>[316,317]</sup>. In a controlled trial that addressed duration of treatment, 12 weeks was better than 4 weeks particularly in 'medical patients'<sup>[318]</sup>. In another study, patients with a first episode of VTE received anticoagulation during 6 weeks or 6 months<sup>[319]</sup>. The incidence of recurrence over 2 years of follow-up was higher (18.1%) in the patient group treated over 6 weeks than in the group treated over 6 months (9.5%). Recent trials demonstrated the benefit of prolonged treatment (6 months) with a decrease of recurrence, particularly in patients with idiopathic VTE<sup>[320]</sup>. For patients with recurrent VTE, a recent trial comparing 6 months of anticoagulation and indefinite duration (>2 years) also showed a reduced recurrent rate with prolonged treatment predominantly in patients with idiopathic episodes<sup>[321]</sup>. Therefore, the low incidence of recurrence of VTE in patients with temporary risk factors suggest that 3–6 months of treatment might be appropriate, whereas long-term oral anticoagulant therapy for 6 months should be considered for patients without predisposing risk factors after a first episode. An indefinite duration of oral anticoagulant therapy should be considered in patients with VTE associated with active malignant disease or with recurrent episodes. A number of trials are in progress to test these recommendations and yield more information on these situations.

The most common complication of oral anticoagulant therapy is bleeding and the risk is related to the intensity of anticoagulation. There is sufficient evidence that bleeding is more common when INR is above 3.0<sup>[315,322]</sup>. Multivariate analysis of cohort studies suggest that bleeding risk is influenced by underlying clinical disorders and age<sup>[295]</sup>. Bleeding complications tend to occur early after induction of treatment and may unmask a lesion such as renal tumour, gastro-intestinal tumour or ulcer, or cerebral aneurysm<sup>[322]</sup>.

If clinically indicated, oral anticoagulant effect can be corrected either by withholding therapy or by oral or parenteral administration of vitamin K1 (1–2 mg). If the patient has serious bleeding, a rapid reversal of the anticoagulant effect could be obtained with i.v. vitamin K and fresh frozen plasma or prothrombin complex concentrate<sup>[323]</sup>.

The most important non-haemorrhagic side effect of oral anticoagulant therapy is skin necrosis, which may occur during the first week of treatment. This complication has been associated with protein C deficiency<sup>[324]</sup>, protein S deficiency<sup>[325]</sup> and malignancy<sup>[326]</sup>.

During pregnancy, oral anticoagulants cross the placenta and are responsible for abortion and embryopathies during the first trimester<sup>[327]</sup>. Therefore, oral anticoagulant therapy should be replaced by heparin treatment during the first trimester of pregnancy and also during the last 6 weeks before delivery due to the bleeding risks. Subcutaneous adjusted UFH or LMWH are the long-term treatment of choice in a pregnant woman<sup>[328]</sup>.

*Summary*

- Patients with PE should be treated with intravenous, weight-adapted UFH, with an adjusted aPTT between 1.5 to 2.5 control (anti Xa activity 0.3–0.6 IU).
- LMWH may be used in patients with symptomatic non-massive PE.
- Oral anticoagulant treatment should be initiated during the first 3 days with an overlap with heparin treatments for at least 4 to 5 days. Heparins could be discontinued when the INR has been therapeutic (range 2.0 to 3.0) for 2 consecutive days.
- Patients with a first episode of PE should be treated for at least 3 months if they have a reversible risk factor and for at least 6 months if they have idiopathic VTE.
- Oral anticoagulants should be continued for a longer period, possibly indefinitely, in patients with recurrent VTE, or continuing risk factors such as cancer.

*Venous filters*

Interruption of the inferior vena cava (IVC) to prevent PE was performed percutaneously routinely in the early 1980s<sup>[329]</sup>. The percutaneous approach allowed the procedure to be performed easily and the use of filters has extensively increased over the years<sup>[328]</sup>. A new concept of temporary filters has recently appeared, which was designed to prevent PE in high risk patients during a short period of time<sup>[331,332]</sup>.

Many devices were developed for the last 15 years, whose principle was to stop emboli and to maintain caval patency. The five most used are: Titanium Greenfield<sup>[333]</sup>, LGM/Venatech<sup>[334]</sup>, Simon Nitinol<sup>[335]</sup> and Bird's nest<sup>[336]</sup> filters. There is no comparative large study to determine which one of these is the most effective in preventing PE. The Greenfield filter has proved to be safe in the supra-renal position and the low occlusion rate could be an argument for using it in prophylaxis of PE in young patients<sup>[337,338]</sup>. If the vena cava is greater than 30 mm diameter, the Bird's nest filter is indicated. Nevertheless, all these filters are prone to complications<sup>[339]</sup>: penetration of the wall of the vena cava and caudal migration were noticed with Greenfield filters and LGM/Venatech once. Insertion site complications, such as DVT and haematomas should be reduced with the use of smaller diameter introducers and jugular vein access.

Prevention of PE: recurrent PE and death are not frequent after IVC interruption but the effectiveness of the filters is difficult to determine because follow-up in most series is incomplete and non-systematic and moreover did not always include objective tests for PE. When pooling multiple studies with Greenfield filters, PE was reported in 2.4% (26/1094 patients) and 2.9% (42/1428)

with the latest devices<sup>[340,341]</sup>. In the only randomized study (PREPIC), 400 patients with DVT (with or without PE) were treated either with anticoagulant (standard heparin vs low molecular weight heparin plus oral anticoagulant) alone or with anticoagulant plus vena cava filter<sup>[342]</sup>. During the first 12 days, the PE rate was 1.1% with filter vs 4.8% with anticoagulant alone ( $P=0.03$ ). However, during the 2-year follow-up, the difference became non-significant—3.4% vs 6.3% ( $P=0.16$ ). Although there is no difference in the total mortality at 12 days (2.5% in each group), four of five deaths in the non-filter group were due to PE vs none of five deaths in the filter group.

Inferior vena cava occlusion and DVT recurrences: filter occlusion may be due to its thrombogenic potential or due to the efficacy against clot migration. When patency was evaluated, obstruction was noticed in 5/81 (6.2%) with Greenfield filters<sup>[340]</sup>. Higher incidence of IVC thrombosis was noticed with new devices 30/272 (11%)<sup>[340]</sup> and recently a long-term follow-up (6 years) showed that 30% of the LGM/Venatech filters were occluded<sup>[341]</sup>. In PREPIC, at 2 years, the recurrence of DVT was significantly more frequent with filters (21%) as compared with conventional treatment without any filter (12%)<sup>[342]</sup>. Furthermore, after a 6 year follow-up, 59% of patients had clinical evidence of venous insufficiency.

Anticoagulant treatment with vena cava filters: adjunctive anticoagulant treatment after filter insertion, if not contra-indicated, might be useful to prevent recurrence of DVT, vena cava occlusion and insertion site DVT. There is no randomized study, but in a Greenfield series with contra-indication to anticoagulant, the occlusion rate was 15%<sup>[343]</sup>, whereas in two other series of new filters and anticoagulant treatment this occlusion rate was only 8%<sup>[344,345]</sup>. Thus, long-term anticoagulant treatment, if not contra-indicated, should be recommended with an INR in the range of 2.0 to 3.0.

Indications for IVC interruption: the three major indications for IVC filters were to prevent PE in patients with DVT or PE who either could not be anticoagulated or who suffered from a PE or recurrent VTE despite adequate anticoagulant treatment and finally after surgical pulmonary embolectomy. Because of a relative safety of the procedure, filters are also used for PE prevention in other situations. In case of free floating thrombus, many filters were inserted. In a recent series, the PE recurrence rate with adequate anticoagulant treatment is low, 3.3% as compared to 3.7% in cases of occlusive thrombus, so this indication is no longer warranted<sup>[65]</sup>. Other prophylactic indications have been suggested: in high risk situations prior to orthopaedic surgery in elderly patients with a history of VTE<sup>[346]</sup>, in patients with minimal cardiopulmonary reserve and/or pulmonary hypertension, prior to thrombolysis of proximal DVT or massive PE<sup>[331]</sup>. Filter insertion was also suggested routinely in trauma patients with head or spinal injury<sup>[347,348]</sup>. But concerning these prophylactic indications, the risks and benefits still remain to be

determined compared to LMWH prophylaxis. Moreover, in such a situation with a short period of time at risk (i.e. after pelvic fracture or hip surgery) the development of a retrievable vena cava filter should be particularly appealing, but so far there is no ideal device and no adequate study<sup>[332,349]</sup>.

#### Summary

- IVC filters are indicated to prevent PE in patients with either absolute anticoagulation contraindications or patients who suffer from recurrent VTE despite adequate anticoagulant treatment.
- IVC filters are probably indicated after surgical embolectomy.
- Retrievable IVC filters require further study to validate their use.

## Specific problems

### Diagnosis and treatment of PE in pregnancy

PE is an uncommon but important cause of maternal death during pregnancy<sup>[350,351]</sup>. It poses specific problems about safety of maternal investigations on the fetus, particularly when these investigations involve ionizing radiation. There is also confusion about the effects that any maternal therapy may have on fetal well-being. No recent data are available on the incidence of DVT and PE during pregnancy. In classic venographic studies, the incidence of DVT during pregnancy was approximately 0.5 per 1000<sup>[352,353]</sup>. The risk of DVT is approximately four times higher in the post-partum period and 20 times higher after a caesarean section. The incidence of PE in pregnancy varies between 1 per 1000 and 1 per 3000 deliveries<sup>[354,355]</sup>. PE remains the leading cause of pregnancy-related maternal death in developed countries<sup>[350,351]</sup>. The increased risk of VTE during pregnancy is due to a combination of hormonal, mechanic and blood composition modifications. A reduction of femoral venous blood flow has been documented in pregnancy<sup>[356,357]</sup>, resulting from the mechanic compression of the iliac veins by the enlarged uterus and decreased venous tone in response to hormonal modifications. The effect is more marked in the veins of the left leg and DVT is more frequent on this side<sup>[358]</sup>. Finally, coagulation factors II, VII and X increase by the third trimester, whereas the levels of coagulation inhibitor protein S and plasma fibrinolytic activity both decrease<sup>[38]</sup>. In summary, pregnancy is a hypercoagulable state, and haemostasis returns to normal 2 weeks after delivery.

The clinical features of PE are no different in pregnancy compared to the non-pregnant state. A recent review suggests that 90% of those with pulmonary embolus have dyspnoea and tachypnoea<sup>[359]</sup>. Hence, the absence of these features excludes PE in most cases. However, pregnant women often present with breath-

**Table 9** Estimated radiation absorbed by fetus in procedures for diagnosing PE<sup>[361,362]</sup>

Test	Estimated radiation (μGy)
Chest radiography	<10
Perfusion lung scan with Technetium-99m macroaggregated albumin (1–2mCi)	60–120
Ventilation lung scan	
with Technetium-99m sulfur colloid	10–50
with Technetium-99m pentetate	70–350
with Xenon-133	40–190
Pulmonary angiography by femoral route	2210–3740
Pulmonary angiography by brachial route	<500
Helical CT (increases with gestational age)	13–300

lessness, and that symptom should be interpreted with caution, especially when isolated, and neither severe nor of acute onset. Basic diagnostic tests (chest X-ray, blood gases and ECG) suffer from the same limitations as in the non-pregnant state. Arterial oxygen pressure ( $P_aO_2$ ) is normal during pregnancy. However, arterial blood should be drawn in the upright position, as the  $P_aO_2$  may be up to 2 kPa lower in the supine position during the third trimester<sup>[360]</sup>.

The amount of radiation absorbed by the fetus for different diagnostic tests is shown in Table 9. A single maternal chest radiograph represents less than 10 μGy, a trivial quantity compared to the 50 000 μGy considered to be the upper limit with regard to danger of injury for the fetus<sup>[361]</sup>. The radiation from one perfusion lung scintigram varies between 10 and 350 μGy and the injected dose may be reduced further in pregnancy<sup>[38]</sup>. Nursing mothers should not breast feed for 15 h after the scan, as significant quantities of 99mTc are secreted in their milk<sup>[359]</sup>. It is likely that ventilation scans add little diagnostic precision in healthy young women. However even if a ventilation scan is used this only increases the radiation by a further 40–190 μGy<sup>[361]</sup>. The radiation from pulmonary angiography is significantly higher (2210 to 3740 μGy), although it is still much below the 50 000 μGy limit, and can be further reduced by using the brachial route. Spiral CT also delivers a significant amount of radiation, however, this is directed at the chest. Recent investigations show that, depending on the fetal age, the fetal dose varies between 13 μGy (12 weeks) and 300 μGy (full-term), and sCT is considered safe in this setting<sup>[362]</sup>. In spite of all these figures being lower than the upper limit, it is better to use as little radiation as possible and use other means.

As in the non-pregnant state, plasma D-dimer measurement should be the initial test in suspected PE. However, as D-dimer plasma concentration rises physiologically throughout pregnancy<sup>[363]</sup>, the proportion of pregnant patients in whom a normal D-dimer level can rule out PE will be lower than in a usual outpatient population. In patients with an abnormal D-dimer level, leg vein imaging should be performed by compression US. The same diagnostic criteria apply to pregnant

patients, and finding a DVT warrants the prescription of anticoagulant treatment. Lung scintigraphy should only be performed in patients with an elevated D-dimer level and a normal US, or if these tests are unavailable. Patients with a non-diagnostic lung scan and a low clinical probability of PE may be discharged without anticoagulant treatment. Finally, most experts agree that the inconvenience of prolonged anticoagulant treatment in a pregnant patient in whom PE is not certain is greater than that of performing pulmonary angiography.

The treatment of PE in pregnancy rests mainly on heparin, either UFH or LMWH, because neither cross the placenta and they are not found in breast milk in any significant amount<sup>[364]</sup>. UFH is still the standard for lack of data on the use of LMWH for treating VTE in pregnancy. After an initial course of i.v. treatment of 5–10 days, at the dose necessary to prolong the aPTT to 1.5–2.5 times the control value, UFH may be given subcutaneously twice a day, with the same target aPTT. Blood should be sampled 6 h after the subcutaneous injection. The heparin treatment should be given throughout the entire pregnancy. After delivery, anticoagulation by warfarin may replace heparin treatment. Anticoagulant treatment should be administered until 6 weeks post-partum, or up to 3 months after acute PE if that exceeds the 6-week period. This can be administered by oral anticoagulants even in breast feeding mothers. The advantages of LMWH in the treatment of VTE during pregnancy are obvious: no monitoring required, and reduced risk of osteoporosis and heparin-induced thrombocytopenia<sup>[365]</sup>. However, published experience is still limited<sup>[328,366]</sup>. The dose of LMWH should be either 200 IU . kg<sup>-1</sup> once a day or 100 IU . kg<sup>-1</sup> twice a day.

Vitamin K antagonists cross the placenta, and warfarin is associated with a characteristic embryopathy during the first trimester<sup>[367,368]</sup>. Its administration in the third trimester can also result in fetal and neonatal haemorrhage and placental abruption<sup>[369]</sup>. Although warfarin may be associated with central nervous system anomalies in any trimester in pregnancy, that risk is very low. Hence, for women having a PE during the first trimester, some experts recommend the cautious use of warfarin during the second trimester of pregnancy, by analogy to a frequently used regimen in pregnant women with mechanical heart valves<sup>[38]</sup>, providing the patient be fully informed and consenting.

To manage labour and delivery, numerous schemes are advocated, of which none have been compared in clinical trials. Subcutaneous heparin injections should be discontinued at the onset of regular uterine contractions<sup>[38]</sup>. Some even advocate that labour be planned, so that heparin may be discontinued 24 h before labour<sup>[370]</sup>. Whether small doses of intravenous UFH (5000 IU every 12 h) should be given during labour is unclear<sup>[371]</sup>. Finally, for patients with PE within the last 3 months, peri-partum intravenous heparin treatment may be used, the infusion being discontinued 4 to 6 h prior to the expected time of delivery<sup>[372]</sup>. The use of epidural analgesia in patients having received their last dose of

heparin in the previous 12 to 24 h (either UF or LMW) is debated. Although the risk of an epidural haematoma is probably very low, several authorities argue against it.

There is published information on 36 women treated with thrombolytic agents in pregnancy, massive PE being the indication in about one third<sup>[373]</sup>. Streptokinase was used most frequently. Streptokinase (and probably other thrombolytic drugs) does not cross the placenta. However in the mother, bleeding is the major side effect, usually from the genital tract and often severe; the overall incidence of bleeding is about 8%. This risk does not seem unreasonable compared to that of massive PE treated by heparin alone. At the time of delivery, thrombolytic treatment should not be used unless it appears that the patient is likely to die and surgical embolectomy is not immediately available. Indications for caval filters in pregnancy are similar to those in the non-pregnant state.

#### Summary

- An accurate diagnosis is mandatory, as pulmonary embolism requires a prolonged course of heparin in pregnant women.
- All diagnostic modalities, including CT scan and angiography, may be used without a significant risk to the fetus.
- The indication for anticoagulant treatment is the same as in the non-pregnant state.
- Coumarins are formally contraindicated during the first trimester and last 6 weeks of pregnancy.
- Long courses of treatment by unfractionated heparin should be administered subcutaneously.
- Low-molecular heparins are probably safe during pregnancy.

#### References

- [1] Karwinski B, Svendsen E. Comparison of clinical and post-mortem diagnosis of pulmonary embolism. *J Clin Path* 1989; 42: 135–9.
- [2] Mandelli V, Schmid C, Zogno C *et al.* 'False negatives' and 'false positives' in acute pulmonary embolism: A clinical-postmortem comparison. *Cardiologia* 1997; 42: 205–10.
- [3] Stein PD, Henry JW. Prevalence of acute pulmonary embolism among patients in a general hospital and at autopsy. *Chest* 1995; 108: 78–81.
- [4] Goldhaber SZ, Visani L, De Rosa M. Acute pulmonary embolism: clinical outcomes in the International Cooperative Pulmonary Embolism Registry (ICOPER). *Lancet* 1999; 353: 1386–9.
- [5] Tibbut DA, Chesterman CN. Pulmonary embolism: current therapeutic concepts. *Drugs* 1976; 11: 161–92.
- [6] Nicolaides AN, Arcelus J, Belcaro G *et al.* Prevention of venous thromboembolism. European consensus conference. *Int Angiology* 1992; 11: 151–9.
- [7] Goldhaber SZ, Morpurgo M. Diagnosis, treatment and prevention of pulmonary embolism. Report of the WHO/ISFC Task Force. *JAMA* 1992; 268: 1727–33.
- [8] Van Beek EJR, ten Cate JW. The diagnosis of venous thromboembolism: an overview. In: Hull RD, Raskob GE,

- Pineo GF, eds. Venous Thromboembolism: an evidence-based atlas. Armonk: Futura Publishing Co, 1996: 93-9.
- [9] Dismuke SE, VanderZwaag R. Accuracy and epidemiological implications of the death certificate diagnosis of pulmonary embolism. *J Chron Dis* 1984; 37: 67-73.
- [10] Stein PD. Pulmonary Embolism. Baltimore: William & Wilkins, 1996: 41-53.
- [11] Morpurgo M, Schmid C. Clinico-pathologic correlations in pulmonary embolism: a *posteriori* evaluation. *Prog Resp Dis* 1980; 13: 8-15.
- [12] Goldhaber SZ. Strategies for diagnosis. In: Goldhaber SZ, ed. Pulmonary Embolism and Deep Vein Thrombosis. Philadelphia: Saunders, 1985: 79-97.
- [13] Rubinstein I, Murray D, Hoffstein V. Fatal pulmonary emboli in hospitalized patients. An autopsy study. *Arch Intern Med* 1988; 148: 1425-6.
- [14] Gross JS, Neufeld RR, Libow LS, Gerber I, Rodstein M. Autopsy study of the elderly institutionalized patient. Review of 234 autopsies. *Arch Intern Med* 1988; 148: 173-6.
- [15] Morpurgo M, Schmid C, Mandelli V. Factors influencing the clinical diagnosis of pulmonary embolism: analysis of 229 postmortem cases. *Int J Cardiol* 1998; 65 (Suppl I): S79-S82.
- [16] Diebold J, Loehrs U. Venous thrombosis and pulmonary embolism. A study of 5039 autopsies. *Path Res Pract* 1991; 187: 260-6.
- [17] Giuntini C, Di Ricco G, Marini C *et al.* Epidemiology. *Chest* 1995; 107 (Suppl I): 3S-9S.
- [18] Ferrari E, Baudouy M, Cerboni P *et al.* Clinical epidemiology of venous thrombo-embolic disease. Results of a French multicentre registry. *Eur Heart J* 1997; 18: 685-91.
- [19] Lane DA, Mannucci PM, Bauer KA *et al.* Inherited thrombophilia: Part 1. *Thromb Haemost* 1996; 76: 651-62.
- [20] Lane DA, Mannucci PM, Bauer KA *et al.* Inherited thrombophilia: Part 2. *Thromb Haemost* 1996; 76: 824-34.
- [21] Dahlback B. Inherited thrombophilia: resistance to activated protein C as a pathogenetic factor of venous thromboembolism. *Blood* 1995; 85: 607-14.
- [22] Bertina RM, Koeleman BPC, Koster T *et al.* Mutation in blood coagulation factor V associated with resistance to activated protein C. *Nature* 1994; 369: 64-7.
- [23] Poort SR, Rosendaal FR, Reitsma PH, Bertina RM. A common genetic variation in the 3'-untranslated region of the prothrombin gene is associated with elevated plasma prothrombin levels and an increase in venous thrombosis. *Blood* 1996; 88: 3698-703.
- [24] Den Heyer M, Koster T, Blom HJ *et al.* Hyperhomocysteinemia as a risk factor for deep-vein thrombosis. *N Engl J Med* 1996; 334: 759-62.
- [25] Fermo I, Viganò D, Angelo S *et al.* Prevalence of moderate hyperhomocysteinemia in patients with early-onset venous and arterial occlusive disease. *Ann Intern Med* 1995; 123: 747-53.
- [26] Demers C, Ginsberg JS, Hirsh J, Henderson P, Blajchman MA. Thrombosis in antithrombin III deficient persons. *Ann Intern Med* 1992; 116: 754-61.
- [27] Heyboer H, Brandjes DPM, Büller HR, Sturk A, ten Cate JW. Deficiencies of coagulation-inhibiting and fibrinolytic proteins in outpatients with deep-vein thrombosis. *N Engl J Med* 1990; 323: 1512-5.
- [28] Piccoli A, Prandoni P, Goldhaber SZ. Epidemiologic characteristics, management, and outcome of deep vein thrombosis in a tertiary care hospital: The Brigham and Women's Hospital DVT Registry. *Am Heart J* 1996; 132: 1010-4.
- [29] Lilienfeld DE, Goldbold JH, Burke GL *et al.* Hospitalization and case fatality for pulmonary embolism in the twin cities: 1979-1984. *Am Heart J* 1990; 120: 392-5.
- [30] Anderson FA, Brownell-Wheeler H, Goldberg RJ *et al.* A population-based perspective of the hospital incidence and case-fatality rates of deep vein thrombosis and pulmonary embolism. *Arch Intern Med* 1991; 151: 933-8.
- [31] Bergqvist D, Lindblad B. Incidence of venous thromboembolism in medical and surgical patients. In: Bergqvist D *et al.*, eds. Prevention of Venous Thromboembolism. London: Med-Orion, 1994: 3-15.
- [32] Kniffin WD, Baron JA, Barrett J *et al.* The epidemiology of diagnose pulmonary embolism and deep vein thrombosis in the elderly. *Arch Intern Med* 1994; 154: 861-6.
- [33] Gallus AS. Medical patients. In: Hull RD, Raskob GE, Pineo GF, eds. Venous Thromboembolism: an evidence-based atlas. Armonk: Futura Publishing Co, 1996: 67-73.
- [34] Turpie AGG, Leclerc JR. Prophylaxis of venous thromboembolism. In: Leclerc JR, ed. Venous Thromboembolic Disorders. Philadelphia: Lea Febiger, 1991: 303-45.
- [35] Josa M, Siouffi SY, Silverman AB *et al.* Pulmonary embolism after cardiac surgery. *J Am Coll Cardiol* 1993; 21: 990-6.
- [36] Malone KM. Coronary artery bypass grafting. In: Goldhaber SZ, ed. Prevention of Venous Thromboembolism. New York: Marcel Dekker, 1993: 439-44.
- [37] Huber O, Bounameaux H, Borst F *et al.* Postoperative pulmonary embolism after hospital discharge. *Arch Surg* 1992; 127: 310-3.
- [38] Togli MR, Weg JG. Venous Thromboembolism During Pregnancy. *N Engl J Med* 1996; 335: 108-13.
- [39] WHO. Venous thromboembolic disease and combined oral contraceptives: results of international multicentre case-control study. *Lancet* 1995; 346: 1575-82.
- [40] Jick H, Jick SS, Gurevich V *et al.* Risk of idiopathic cardiovascular death and non-fatal venous thromboembolism in women using oral contraceptives with different prostatic compounds. *Lancet* 1995; 346: 1589-93.
- [41] Spitzer WO, Lewis MA, Heinemann LAJ *et al.* Third generation oral contraceptives and risk of venous thromboembolic disorders: an international case-control study. *Br Med J* 1996; 312: 83-8.
- [42] Grodstein F, Stampfer MJ, Goldhaber SZ *et al.* Prospective study of exogenous hormones and risk of pulmonary embolism in women. *Lancet* 1996; 348: 983-7.
- [43] Hulley S, Grady D, Bush T *et al.* Randomized trial of estrogen plus progestin for secondary prevention of coronary heart disease in postmenopausal women. Heart and Estrogen/progestin Replacement Study (HERS) Research Group. *JAMA* 1998; 280: 605-13.
- [44] Goldhaber SZ, Grodstein F, Stampfer MJ *et al.* A prospective study of risk factors for pulmonary embolism in women. *JAMA* 1997; 277: 642-5.
- [45] Baron JA, Gridley G, Weiderpass E, Nyren O, Linet M. Venous thromboembolism and cancer. *Lancet* 1998; 351: 1077-80.
- [46] Cornuz J, Pearson SD, Creager MA, Cook EF, Goldman L. Importance of findings on the initial evaluation for cancer in patients with symptomatic idiopathic deep venous thrombosis. *Ann Intern Med* 1996; 125: 785-93.
- [47] Sorensen HT, Mellekjaer L, Steffensen FH, Olsen JH, Nielsen GL. The risk of a diagnosis of cancer after primary deep venous thrombosis or pulmonary embolism. *N Engl J Med* 1998; 338: 1169-73.
- [48] Hume M, Sevitt S, Thomas DP. Venous Thrombosis and Pulmonary Embolism. Cambridge: Harvard University Press, 1970: 206-7.
- [49] Monreal M, Lafoz E, Ruiz J *et al.* Upper-extremity deep venous thrombosis and pulmonary embolism. *Chest* 1991; 99: 280-3.
- [50] Polak JF. Venous ultrasound and doppler sonography. In: Goldhaber SZ, ed. Prevention of Venous Thromboembolism. New York: Marcel Dekker, 1993: 87-126.
- [51] Moser KM. Pulmonary Embolism. *Am Rev Resp Dis* 1977; 115: 829-52.
- [52] Prandoni P, Polistena P, Bernardi E *et al.* Upper-extremity deep vein thrombosis. Risk factors, diagnosis, and complications. *Arch Intern Med* 1997; 157: 57-62.
- [53] Coon WW, Collier FA. Clinicopathologic correlation in thromboembolism. *Surg Gyn Obst* 1959; 109: 259-69.

- [54] Koehn H, Koenig B, Mostbeck A. Incidence and clinical feature of pulmonary embolism in patients with deep vein thrombosis: a prospective study. *Eur J Nucl Med*, 1987; 13: S11-S15.
- [55] Kakkar VV, Flanc C, Howe CT, Clarke MB. Natural history of postoperative deep-vein thrombosis. *Lancet* 1969; 2: 230-2.
- [56] Sasahara AA, McIntyre KM, Cella G *et al.* The clinical and hemodynamic features of acute pulmonary embolism. *Curr Pulmonol* 1988; 9: 305-46.
- [57] Colman NC. Pathophysiology of pulmonary embolism. In: Leclerc JR, ed. *Venous Thromboembolic Disorders*. Philadelphia: Lea Febiger, 1991: 65-73.
- [58] Menzel T, Wagner S, Kramm T *et al.* Pathophysiology of impaired right and left ventricular function in chronic embolic pulmonary hypertension. *Chest* 2000 (in press).
- [59] Dantzker DR. Pulmonary gas exchange. In: Dantzker DR, ed. *Cardiopulmonary Critical Care*. Orlando: Grune Stratton, 1986: 25-46.
- [60] Sergysels R. Pulmonary gas exchange abnormalities in pulmonary embolism. In: Morpurgo M, ed. *Pulmonary Embolism*. New York: Marcel Dekker, 1994: 89-96.
- [61] Dalen JE, Haffajee CI, Alpert JS *et al.* Pulmonary embolism, pulmonary hemorrhage and pulmonary infarction. *N Engl J Med* 1977; 296: 1431-5.
- [62] Leclerc JR. Natural history of venous thromboembolism. In: Leclerc JR, ed. *Venous Thromboembolic Disorders*. Philadelphia: Lea Febiger, 1991: 166-75.
- [63] Neuhof H. Venous Thrombosis and Pulmonary Embolism. New York: Grune Stratton, 1948: 92-105.
- [64] Morpurgo M, Rustici A. Lo spettro dell'embolia polmonare. *Cardiologia* 1988; 33: 1105-8.
- [65] Pacouret G, Alison D, Pottier JM *et al.* Free-floating thrombus and embolic risk in patients with angiographically confirmed proximal deep venous thrombosis. a prospective study. *Arch Intern Med* 1997; 157: 305-8.
- [66] Barritt DW, Jordan SC. Clinical features of pulmonary embolism. *Lancet* 1961; 1: 729-32.
- [67] Goldhaber SZ, Hennekens CH, Evans D, Newton EC, Godleski JJ. Factors associated with correct antemortem diagnosis of major pulmonary embolism. *Am J Med* 1982; 73: 822-6.
- [68] Kasper W, Konstantinides S, Tiede N *et al.* Prognostic significance of right ventricular afterload stress detected by echocardiography in patients with clinically suspected pulmonary embolism. *Heart* 1997; 77: 346-9.
- [69] Ribeiro A, Lindmarker P, Juhlin-Dannfelt A *et al.* Echocardiography doppler in pulmonary embolism: right ventricular dysfunction as a predictor of mortality rate. *Am Heart J* 1997; 134: 479-87.
- [70] Konstantinides S, Geibel A, Kasper W *et al.* Patent foramen ovale is an important predictor of adverse outcome in patients with major pulmonary embolism. *Circulation* 1988; 97: 1946-51.
- [71] Farfel Z, Shechter M, Vered Z *et al.* Review of echocardiographically diagnosed right heart entrapment of pulmonary emboli-in-transit with emphasis on management. *Am Heart J* 1987; 113: 171-8.
- [72] Kinney REL, Wright RJ. Efficacy of treatment of patients with echocardiographically detected right-sided heart thrombi: A meta-analysis. *Am Heart J* 1989; 118: 569-73.
- [73] Kronik G. The European cooperative study on the clinical significance of right heart thrombi. *Eur Heart J* 1989; 10: 1046-59.
- [74] Chartier L, Bera J, De Lomez M *et al.* Free floating thrombi in the right heart, diagnosis, management and prognostic indexes in 38 consecutive patients. *Circulation* 1999; 99: 2779-83.
- [75] Casazza F, Bongarzone A, Centonze F *et al.* Prevalence and prognostic significance of right-sided cardiac mobile thrombi in acute massive pulmonary embolism. *Am J Cardiol* 1997; 79: 1433-5.
- [76] Widimský J. Mechanisms in embolic pulmonary hypertension. In: Wagenvoort CA, Denolin H, eds. *Pulmonary Circulation, Advances and Controversies*. Amsterdam: Elsevier, 1989: 75-86.
- [77] Riedel M, Stanek V, Widimsky J, Prerovsky L. Long-term follow-up of patients with pulmonary thromboembolism. Late prognosis and evaluation of hemodynamic and respiratory data. *Chest* 1982; 81: 151-8.
- [78] Stein PD, Terrin ML, Hales CA *et al.* Clinical, laboratory, roentgenographic, and electrocardiographic findings in patients with acute pulmonary embolism and no pre-existing cardiac or pulmonary disease. *Chest* 1991; 100: 598-603.
- [79] Palla A, Petruzzelli S, Donnataria V, Giuntini C. The role of suspicion in the diagnosis of pulmonary embolism. *Chest* 1995; 107: 21S-24S.
- [80] Miniati M, Prediletto R, Formichi B *et al.* Accuracy of clinical assessment in the diagnosis of pulmonary embolism. *Am J Respir Crit Care Med* 1999; 159: 864-71.
- [81] Stein PD, Goldhaber SZ, Henry JW, Miller AC. Arterial blood gas analysis in the assessment of suspected acute pulmonary embolism. *Chest* 1996; 109: 78-81.
- [82] Perrier A, Bounameaux H, Morabia A *et al.* Diagnosis of pulmonary embolism by a decision analysis-based strategy including clinical probability, D-dimer levels, and ultrasonography: a management study. *Arch Intern Med* 1996; 156: 531-6.
- [83] Perrier A, Desmarais S, Miron MJ *et al.* Noninvasive diagnosis of venous thromboembolism. *Lancet* 1999; 353: 190-5.
- [84] Perrier A, Miron MJ, Desmarais S *et al.* Combining clinical probability and lung scan in suspected pulmonary embolism. *Arch Intern Med* 2000; 160: 512-6.
- [85] The PIOPED Investigators. Value of the ventilation-perfusion scan in acute pulmonary embolism. *JAMA* 1990; 263: 2753-9.
- [86] Wells PS, Ginsberg JS, Anderson DR *et al.* Use of a clinical model for safe management of patients with suspected pulmonary embolism. *Ann Intern Med* 1998; 129: 997-1005.
- [87] Celi A, Palla A, Petruzzelli S *et al.* Prospective study of a standardized questionnaire to improve clinical estimate of pulmonary embolism. *Chest* 1989; 95: 332-7.
- [88] Hoellerich VL, Wigton RS. Diagnosing pulmonary embolism using clinical findings. *Arch Intern Med* 1986; 146: 1699-704.
- [89] Wasson JH, Sox HC. Clinical prediction rules. Have they come of age? *JAMA* 1996; 275: 641-2.
- [90] Wyatt JC, Atman DG. Prognostic models: clinically useful or quickly forgotten? *Br Med J* 1995; 311: 1539-41.
- [91] The PISA-PED Investigators. Value of perfusion lung scan in the diagnosis of pulmonary embolism: results of the prospective study of acute pulmonary embolism diagnosis (PISA-PED). *Am J Respir Crit Care Med* 1996; 154: 1387-93.
- [92] Miller RF, O'Doherty MJ. Pulmonary nuclear medicine. *Eur J Nucl Med* 1992; 19: 355-68.
- [93] Dalen JE, Haynes FW, Hoppin FG Jr, Evans GL, Bhardwaj P, Dexter L. Cardiovascular responses to experimental pulmonary embolism. *Am J Cardiol* 1967; 20: 3-9.
- [94] White PG, Hayward MWJ, Cooper T. Ventilation agents — what agents are currently used? *Nucl Med Comm* 1991; 12: 349-52.
- [95] McNeil BJ, Holman BL, Adelstein SJ. The scintigraphic definition of pulmonary embolism. *JAMA* 1974; 227: 753-6.
- [96] Biello DR, Mattar A, McKnight RC, Siegel BA. Ventilation-perfusion studies in suspected pulmonary embolism. *Am J Roentgenol* 1979; 133: 1033-7.
- [97] Hull RD, Raskob GE. Low-probability lung scan findings: a need for change. *Ann Intern Med* 1991; 114: 142-3.
- [98] Gottschalk A, Sostman HD, Coleman RE *et al.* Ventilation-perfusion scintigraphy in the PIOPED study. Part II. Evaluation of the scintigraphic criteria and interpretations. *J Nucl Med* 1993; 34: 1119-26.

- [99] Sostman HD, Coleman RE, DeLong DM, Newman GE, Paine S. Evaluation of revised PIOPED criteria for ventilation perfusion scintigraphy in patients with suspected pulmonary embolism. *Radiology* 1994; 193: 103–7.
- [100] Hull RD, Hirsh J, Carter CJ *et al.* Diagnostic value of ventilation-perfusion lung scanning in patients with suspected pulmonary embolism. *Chest* 1985; 88: 819–28.
- [101] Stein PD, Hull RD, Saltzman HA, Pineo G. Strategy for diagnosis of patients with suspected acute pulmonary embolism. *Chest* 1993; 103: 1553–9.
- [102] Van Beek EJR, Tiel-van Buul MMC, Büller HR, van Royen EA, ten Cate JW. The value of lung scintigraphy in the diagnosis of pulmonary embolism. *Eur J Nucl Med* 1993; 20: 173–81.
- [103] Ginsberg JS. Management of venous thromboembolism. *N Engl J Med* 1996; 335: 1816–28.
- [104] Bateman NT, Coakley AJ, Croft DN, Lyall JRW. Ventilation-perfusion lung scans for pulmonary embolism. Accuracy of reporting. *Eur J Nucl Med* 1977; 2: 201–3.
- [105] Hoey JR, Farrer PA, Rosenthal LJ, Spengler RF. Inter-observer and intra-observer variability in lung scan reading in suspected pulmonary embolism. *Clin Nucl Med* 1980; 5: 509–13.
- [106] Sullivan DC, Coleman RE, Mills SR, Ravin CE, Hedlund LW. Lung scan interpretation: effect of different observers and different criteria. *Radiology* 1983; 149: 803–7.
- [107] Lensing AWA, van Beek EJR, Demers C *et al.* Ventilation-perfusion lung scanning and the diagnosis of pulmonary embolism: improvement of observer agreement by the use of a lung segment reference chart. *Thromb Haemost* 1992; 68: 245–9.
- [108] Van Beek EJR, Tiel-van Buul MMC, Hoefnagel CA, Jagt HHT, van Royen EA. Reporting of perfusion-ventilation lung scintigraphy with the use of an anatomical lung segment chart — a prospective study. *Nucl Med Commun* 1994; 15: 746–51.
- [109] Kipper MS, Moser KM, Kortman KE, Ashburn WL. Long-term follow-up of patients with suspected pulmonary embolism and a normal lung scan. *Chest* 1982; 82: 411–5.
- [110] Hull RD, Raskob GE, Coates G, Panju AA. Clinical validity of a normal perfusion lung scan in patients with suspected pulmonary embolism. *Chest* 1990; 97: 23–6.
- [111] Van Beek EJR, Kuyper PMM, Schenk BE, Brandjes DPM, ten Cate JW, Büller HR. A normal perfusion lung scan in patients with clinically suspected pulmonary embolism: frequency and clinical validity. *Chest* 1995; 108: 170–3.
- [112] Cheely R, McCartney WH, Perry JR *et al.* The role of noninvasive tests versus pulmonary angiography in the diagnosis of pulmonary embolism. *Am J Med* 1981; 70: 17–22.
- [113] McBride K, LaMorte WW, Menzies JO. Can ventilation-perfusion scans accurately diagnose acute pulmonary embolism? *Arch Surg* 1986; 121: 754–7.
- [114] Hull RD, Raskob GE, Carter CJ *et al.* Pulmonary embolism in outpatients with pleuritic chest pain. *Arch Intern Med* 1988; 148: 838–44.
- [115] Alderson PO, Biello DR, Sachariah KG, Siegel BA. Scintigraphic detection of pulmonary embolism in patients with obstructive pulmonary disease. *Radiology* 1981; 138: 661–6.
- [116] Spies WG, Burstein SP, Dillehay GL, Vogelzang RL, Spies SM. Ventilation-perfusion scintigraphy in suspected pulmonary embolism: correlation with pulmonary angiography and refinement of criteria for interpretation. *Radiology* 1986; 159: 383–90.
- [117] Gray HW, McKillop JH, Bessent RG, Fogelman I, Smith ML, Moran F. Lung scanning for pulmonary embolism: clinical and pulmonary angiographic correlations. *Q J Med* 1990; 77: 1135–50.
- [118] McNeil BJ. A diagnostic strategy using ventilation-perfusion studies in patients suspected for pulmonary embolism. *J Nucl Med* 1976; 17: 613–6.
- [119] Fischer KC, McNeil BJ. The indeterminate lung scan: its characteristics and its association with pulmonary embolism. *Eur J Nucl Med* 1979; 4: 49–53.
- [120] Van Beek EJR, Reekers JA, Batchelor D, Brandjes DPM, Peeters FLM, Büller HR. Feasibility, safety and clinical utility of angiography in patients with suspected pulmonary embolism and non-diagnostic lung scan findings. *Eur Radiol* 1996; 6: 415–9.
- [121] Lesser BA, Leeper KV, Stein PD *et al.* The diagnosis of acute pulmonary embolism in patients with chronic obstructive pulmonary disease. *Chest* 1992; 102: 17–22.
- [122] Ludwig JW. Heart and coronaries — the pioneering age. In: Rosenbusch G, Oudkerk M, Amman E. *Radiology in medical diagnostics — evolution of X-ray applications 1895–1995*. Oxford: Blackwell Science, 1995: 213–24.
- [123] Dalen JE, Brooks HL, Johnson LW *et al.* Pulmonary angiography in acute pulmonary embolism: indications, techniques, and results in 367 patients. *Am Heart J* 1971; 81: 175–85.
- [124] Sasahara AA, Hyers TM, Cole CM *et al.* The urokinase pulmonary embolism trial. *Circulation* 1973; 47: 1–108.
- [125] Bell WR, Simon TL. A comparative analysis of pulmonary perfusion scans with pulmonary angiograms. *Am Heart J* 1976; 92: 700–6.
- [126] Mills SR, Jackson DC, Older RA *et al.* The incidence, etiologies, and avoidance of complications of pulmonary angiography in a large series. *Radiology* 1980; 136: 295–9.
- [127] Stein PD, Athanasoulis C, Alavi A *et al.* Complications and validity of pulmonary angiography in acute pulmonary embolism. *Circulation* 1992; 85: 462–8.
- [128] Van Rooy WJJ, den Heeten GJ, Sluzewski M. Pulmonary embolism: diagnosis in 211 patients with use of selective pulmonary digital subtraction angiography with a flow-directed catheter. *Radiology* 1995; 195: 793–7.
- [129] Hudson ER, Smith TP, McDermott VG *et al.* Pulmonary angiography performed with iopamidol: complications in 1434 patients. *Radiology* 1996; 198: 61–5.
- [130] Van Beek EJR, Reekers JA, Batchelor D, Brandjes DPM, Peeters FLM, Büller HR. Feasibility, safety and clinical utility of angiography in patients with suspected pulmonary embolism and non-diagnostic lung scan findings. *Eur Radiol* 1996; 6: 415–9.
- [131] Zuckerman DA, Sterling KM, Oser RF. Safety of pulmonary angiography in the 1990s. *J Vasc Intervent Radiology* 1996; 7: 199–205.
- [132] Nilsson T, Carlsson A, Mare K. Pulmonary angiography: a safe procedure with modern contrast media and technique. *Eur Radiol* 1998; 8: 86–9.
- [133] Oudkerk M, van Beek EJR, Reekers JA. Pulmonary angiography: technique, indications and interpretations. In: Oudkerk M, van Beek EJR, ten Cate JW eds. *Pulmonary Embolism*. Berlin: Blackwell Science, 1999: 135–59.
- [134] Perlmutter LM, Braun SD, Newman GE, Oke EJ, Dunnick NR. Pulmonary arteriography in the high-risk patient. *Radiology* 1987; 162: 187–9.
- [135] Nicod P, Peterson K, Levine M *et al.* Pulmonary angiography in severe chronic pulmonary hypertension. *Ann Intern Med* 1987; 107: 565–8.
- [136] Grollman JH, Gyepes MT, Helmer E. Transfemoral selective bilateral pulmonary arteriography with a pulmonary artery seeking catheter. *Radiology* 1970; 96: 102–4.
- [137] Van Beek EJR, Bakker AJ, Reekers JA. Interobserver variability of pulmonary angiography in patients with non-diagnostic lung scan results: conventional versus digital subtraction arteriography. *Radiology* 1996; 198: 721–4.
- [138] Saeed M, Braun SD, Cohan RH *et al.* Pulmonary angiography with iopamidol: patient comfort, image quality and hemodynamics. *Radiology* 1987; 165: 345–9.
- [139] Tajima H, Kumazaki T, Tajima N, Ebata K. Effect of iohexol and diatrizoate on pulmonary arterial pressure following pulmonary angiography. *Acta Radiol Scand* 1988; Suppl 29: 487–90.
- [140] Smit EMT, van Beek EJR, Bakker AJ, Reekers JA. A blind, randomized trial evaluating the hemodynamic effects of

- contrast media during pulmonary angiography for suspected pulmonary embolism — ioxaglate vs iohexol. *Acad Radiol* 1995; 2: 609–13.
- [141] Johnson MS, Stine SB, Shah H, Harris VJ, Ambrosius WT, Trerotola SO. Possible pulmonary embolus: evaluation with digital subtraction versus cut-film angiography — prospective study in 80 patients. *Radiology* 1998; 207: 131–8.
- [142] Hagspiel KD, Polak JF, Grassi CJ, Faitelson BB, Kandarpa K, Meyerovitz MF. Pulmonary embolism: comparison of cut-film and digital pulmonary angiography. *Radiology* 1998; 207: 139–45.
- [143] Piers DB, Verzijlbergen F, Westermann CJJ, Ludwig JW. A comparative study of intravenous digital subtraction angiography and ventilation perfusion scans in suspected pulmonary embolism. *Chest* 1987; 91: 837–44.
- [144] Musset D, Rosso J, Petiptretz P *et al.* Acute pulmonary embolism: diagnostic value of digital subtraction angiography. *Radiology* 1986; 166: 455–9.
- [145] Pond GD, Ovitt TW, Capp MP. Comparison of conventional pulmonary angiography with intravenous digital subtraction angiography for pulmonary embolic disease. *Radiology* 1983; 147: 345–50.
- [146] Johnson BA, James AE. Oblique and selective pulmonary angiography in diagnosis of pulmonary embolism. *Am J Roentgenol* 1973; 118: 801–8.
- [147] Bookstein JJ. Segmental arteriography in pulmonary embolism. *Radiology* 1969; 93: 1007–12.
- [148] Hull RD, Hirsh J, Carter CJ *et al.* Pulmonary angiography, ventilation lung scanning, and venography for clinically suspected pulmonary embolism with abnormal perfusion lung scan. *Ann Intern Med* 1983; 98: 891–9.
- [149] Quinn MF, Lundell CJ, Klotz TA *et al.* Reliability of selective pulmonary arteriography in the diagnosis of pulmonary embolism. *Am J Roentgenol* 1987; 149: 469–71.
- [150] Oser RF, Zuckerman DA, Gutierrez FR, Brink JA. Anatomic distribution of pulmonary emboli at pulmonary angiography: implications for cross-sectional imaging. *Radiology* 1996; 199: 31–5.
- [151] Novelline RA, Baltarowich OH, Athanasoulis CA *et al.* The clinical course of patients with suspected pulmonary embolism and a negative pulmonary arterio-gram. *Radiology* 1978; 126: 561–7.
- [152] Henry JW, Relyea B, Stein PD. Continuing risk of thromboemboli among patients with normal pulmonary angiograms. *Chest* 1995; 107: 1375–8.
- [153] Remy-Jardin M, Remy J, Wattinne L, Giraud F. Central pulmonary thromboembolism: diagnosis with spiral volumetric CT with single-breath-hold technique — comparison with pulmonary angiography. *Radiology* 1992; 185: 381–7.
- [154] Teigen CL, Maus TP, Sheedy II PF, Johnson CM, Stanson AW, Welch TJ. Pulmonary embolism: diagnosis with electron-beam CT. *Radiology* 1993; 188: 839–45.
- [155] Van Rossum AB, Pattynama PMT, Tjin A *et al.* Pulmonary embolism: Validation of spiral CT-angiography in 124 patients. *Radiology* 1996; 201: 467–70.
- [156] Remy-Jardin M, Remy J, Artaud D, Deschildre F, Duhamel A. Peripheral pulmonary arteries: Optimization of the spiral CT acquisition protocol. *Radiology* 1997; 204: 157–63.
- [157] Kalender WA, Polacin A. Physical performance characteristics of spiral CT scanning. *Med Phys* 1991; 18: 910–15.
- [158] Remy-Jardin M, Remy J, Deschildre F *et al.* Diagnosis of pulmonary embolism with spiral CT: comparison with pulmonary angiography and scintigraphy. *Radiology* 1996; 200: 699–706.
- [159] Schnyder P, Meuli R, Wicky S, Mayor B. Injection techniques in helical CT of the chest. *Eur Radiol* 1995; 5: 26–33.
- [160] Goodman LR, Curtin JJ, Mewissen MW *et al.* Detection of pulmonary embolism in patients with unresolved clinical and scintigraphic diagnosis: Helical CT versus angiography. *Am J Roentgenol* 1995; 164: 1369–74.
- [161] Remy-Jardin M, Remy J, Cauvain O, Petyt L, Wannebroucq J, Beregi JP. Diagnosis of central pulmonary embolism with helical CT: role of two-dimensional multiplanar reformations. *Am J Roentgenol* 1992; 165: 1131–8.
- [162] Coche EC, Mueller NL, Kim K, Wiggs B, Mayo J. Acute pulmonary embolism: ancillary findings at spiral CT. *Radiology* 1998; 207: 753–8.
- [163] Herold CJ, Kontrus M, Ziesche G, Fleischmann D, Wegerle T, Huebsch. Evaluation of pulmonary embolism: value of 3D and multiplanar cine spiral CT angiography. *Radiology* 1993; 189 (P): 264.
- [164] Schwickert HC, Schweden FJ, Schild HH *et al.* Pulmonary arteries and lung parenchyma in chronic pulmonary embolism: preoperative and postoperative CT findings. *Radiology* 1994; 191: 351–7.
- [165] Mayo JR, Remy-Jardin M, Müller NL *et al.* Pulmonary embolism: prospective comparison of spiral CT with ventilation/perfusion scintigraphy. *Radiology* 1997; 205: 447–52.
- [166] Drucker E, Rivitz M, Shepard J *et al.* Acute pulmonary embolism: assessment of helical CT for diagnosis. *Radiology* 1998; 209: 235–41.
- [167] Garg K, Welsh C, Feyerabend A *et al.* Pulmonary embolism: diagnosis with spiral CT and ventilation-perfusion scanning — correlation with pulmonary angiographic results or clinical outcome. *Radiology* 1998; 208: 201–8.
- [168] Kim K, Müller NL, Mayo JR. Clinically suspected pulmonary embolism: utility of spiral-CT. *Radiology* 1999; 210: 693–7.
- [169] Balle EM, Mayo JR, King GG, Muller NL, Coche EC, Pare PD. Contrast-enhanced spiral-CT is comparable to pulmonary angiography for the diagnosis of pulmonary embolism. *Radiology* 1999; 213 (P): 127.
- [170] Van Erkel AR, van Rossum AB, Bloem JL *et al.* Spiral CT angiography for suspected pulmonary embolism: cost-effectiveness analysis. *Radiology* 1996; 201: 29–36.
- [171] Ferretti GR, Bosson J-L, Buffaz P-D *et al.* Acute pulmonary embolism: role of helical CT in 164 patients with intermediate probability at V/Q scintigraphy and normal results at duplex US of the legs. *Radiology* 1998; 205: 453–8.
- [172] Krestan CR, Klein N, Kreuzer S, Minar E, Janeta J, Herold CJ. Value of a negative spiral-CT angiography in patients with suspected acute PE: retrospective analysis of PE recurrence and outcome. *Eur Radiol* 2000 (in press).
- [173] Goodman LR, Lipchik RJ. Diagnosis of acute pulmonary embolism: time for a new approach. *Radiology* 1996; 199: 25–7.
- [174] Janata-Schwartzek K, Weiss K, Riezinger I, Bankier A, Domanovits H, Seidler D. Pulmonary embolism II: diagnosis and treatment. *Sem Thromb Hemostas* 1996; 22: 33–52.
- [175] Curtin JJ, Mewissen MW, Crain MR, Lipchik RJ. Post-contrast CT in the diagnosis and assessment of response to thrombolysis in massive pulmonary embolism. *J Comput Assist Tomogr* 1994; 18: 133–5.
- [176] Remy-Jardin M, Louvegny S, Remy J *et al.* Acute central thromboembolic disease: post-therapeutic follow-up with spiral CT angiography. *Radiology* 1997; 203: 173–80.
- [177] Kasper W, Konstantinides S, Geibel A *et al.* Management strategies and determinants of outcome in acute major pulmonary embolism: results of a multicenter registry. *J Am Coll Cardiol* 1997; 30: 1165–71.
- [178] Nazeyrollas P, Metz D, Jolly D *et al.* Use of transthoracic Doppler echocardiography combined with clinical and electrocardiographic data to predict acute pulmonary embolism. *Eur Heart J* 1996; 17: 779–86.
- [179] McConnell MV, Solomon SD, Rayan ME, Come PC, Goldhaber SZ, Lee RT. Regional right ventricular dysfunction detected by echocardiography in acute pulmonary embolism. *Am J Cardiol* 1996; 78: 469–73.
- [180] Torbicki A, Kurzyna M, Czurzynski M *et al.* Proximal pulmonary emboli modify right ventricular ejection pattern. *Eur Respir J* 1999; 13: 616–21.

- [181] Wolfe MW, Lee RT, Feldstein ML, Parker JA, Come PC, Goldhaber SZ. Prognostic significance of right ventricular hypokinesis and perfusion lung scan defects in pulmonary embolism. *Am Heart J* 1994; 127: 1371-5.
- [182] Cheriex EC, Sreeram N, Eussen YF, Pieters FA, Wellens HJ. Cross sectional Doppler echocardiography as the initial technique for the diagnosis of acute pulmonary embolism. *Br Heart J* 1994; 72: 52-7.
- [183] Kasper W, Geibel A, Tiede N *et al.* Distinguishing between acute and subacute massive pulmonary embolism by conventional and Doppler echocardiography. *Br Heart J* 1993; 70: 352-6.
- [184] Wittlich N, Erbel R, Eichler A *et al.* Detection of central pulmonary artery thromboemboli by transesophageal echocardiography in patients with severe pulmonary embolism. *J Am Soc Echocardiogr* 1992; 5: 515-24.
- [185] Pruszczyk P, Torbicki A, Pacho R *et al.* Noninvasive diagnosis of suspected severe pulmonary embolism: transesophageal echocardiography vs spiral CT. *Chest* 1997; 112: 722-8.
- [186] Patel JJ, Chandrasekaran K, Maniet AR *et al.* Impact of the incidental diagnosis of clinically unsuspected central pulmonary artery thromboembolism in treatment of critically ill patients. *Chest* 1994; 105: 986-90.
- [187] Krivec B, Voga G, Zuran I *et al.* Diagnosis and treatment of shock due to massive pulmonary embolism: approach with transesophageal echocardiography and intrapulmonary thrombolysis. *Chest* 1997; 112: 1310-6.
- [188] Van der Wouw PA, Koster RW, Delemarre BJ *et al.* Diagnostic accuracy of transesophageal echocardiography during cardiopulmonary resuscitation. *J Am Coll Cardiol* 1997; 30: 780-3.
- [189] Torbicki A, Pasierski T, Uchman B, Miskiewicz Z. Right atrial mobile thrombi: two-dimensional echocardiographic diagnosis and clinical outcome. *Cor Vasa* 1987; 29: 293-303.
- [190] Chapoutot L, Nazeyrollas P, Metz D *et al.* Floating right heart thrombi and pulmonary embolism: diagnosis, outcome and therapeutic management. *Cardiology* 1996; 87: 169-74.
- [191] Kasper W, Geibel A, Tiede N, Just H. Patent foramen ovale in patients with haemodynamically significant pulmonary embolism. *Lancet* 1992; 340: 561-4.
- [192] Ribeiro A, Lindmarker P, Johnsson H, Juhlin-Dannfelt A, Jorfeldt L. Pulmonary embolism: one-year follow-up with echocardiography doppler and five-year survival analysis. *Circulation* 1999; 99: 1325-30.
- [193] Porter TR, Taylor DO, Fields J *et al.* Direct in vivo evaluation of pulmonary arterial pathology in chronic congestive heart failure with catheter-based intravascular ultrasound imaging. *Am J Cardiol* 1993; 71: 754-7.
- [194] Gorge G, Erbel R, Schuster S *et al.* Intravascular ultrasound in diagnosis of acute pulmonary embolism. *Lancet* 1991; 337: 623-4.
- [195] Gorge G, Schuster S, Ge J *et al.* Intravascular ultrasound in patients with acute pulmonary embolism after treatment with intravenous urokinase and high-dose heparin. *Heart* 1997; 77: 73-7.
- [196] Ricou F, Nicod PH, Moser KM *et al.* Catheter-based intravascular ultrasound imaging of chronic thromboembolic pulmonary disease. *Am J Cardiol* 1991; 67: 749-52.
- [197] Sevitt S, Gallagher NG. Venous thrombosis and pulmonary embolism: a clinicopathologic study in injured and burned patients. *Br J Surg* 1961; 48: 475-82.
- [198] Hull RD, Hirsh J, Carter C *et al.* Diagnostic efficacy of impedance plethysmography for clinically suspected deep-vein thrombosis. *Ann Intern Med* 1985; 102: 21-8.
- [199] Ginsberg JS, Wells PS, Hirsh J *et al.* Reevaluation of the sensitivity of impedance plethysmography for the detection of proximal deep vein thrombosis. *Arch Intern Med* 1994; 154: 1930-3.
- [200] Heijboer H, Büller HR, Lensing AWA, Turpie AGG, Colly LP, ten Cate JW. A comparison of real-time compression ultrasonography with impedance plethysmography for the diagnosis of deep-vein thrombosis in symptomatic outpatients. *N Engl J Med* 1993; 329: 1365-9.
- [201] Becker DM, Philbrick JT, Abbitt PL. Real-time ultrasonography for the diagnosis of lower extremity deep venous thrombosis. The wave of the future? *Arch Intern Med* 1989; 149: 1731-4.
- [202] Lensing AWA, Prandoni P, Brandjes D *et al.* Detection of deep-vein thrombosis by real-time B-mode ultrasonography. *N Engl J Med* 1989; 320: 342-5.
- [203] Stein PD, Henry JW, Gopalakrishnan D, Relyea B. Asymmetry of the calves in the assessment of patients with suspected acute pulmonary embolism. *Chest* 1995; 107: 936-9.
- [204] Turkstra F, Kuijter PMM, van Beek EJR, Brandjes DPM, ten Cate JW, Büller HR. Diagnostic utility of ultrasonography of leg veins in patients suspected of having pulmonary embolism. *Ann Intern Med* 1997; 126: 775-81.
- [205] Wells PS, Lensing AWA, Davidson BL, Prins MH, Hirsh J. Accuracy of ultrasound for the assessment of deep venous thrombosis in asymptomatic patients after orthopedic surgery. *Ann Intern Med* 1995; 122: 47-53.
- [206] Killewich LA, Bedford GR, Beach KW, Strandness DE. Diagnosis of deep venous thrombosis. A prospective study comparing duplex scanning to contrast venography. *Circulation* 1989; 79: 810-14.
- [207] Perrier A, Desmarais S, Goehring C *et al.* D-dimer testing for suspected pulmonary embolism in outpatients. *Am J Respir Crit Care Med* 1997; 156: 492-6.
- [208] Smith LL, Conrad I, Sirt S. Pulmonary embolism: confirmation with venous duplex US as adjunct to lung scanning. *Radiology* 1994; 191: 143-7.
- [209] Quinn RJ, Nour R, Butler SP *et al.* Pulmonary embolism in patients with intermediate probability lung scans: diagnosis with Doppler venous US and D-Dimer measurement. *Radiology* 1994; 190: 509-11.
- [210] Beecham RP, Dorfman GS, Cronan JJ, Spearman MP, Murphy TP, Scola FH. Is bilateral lower extremity compression sonography useful and cost-effective in the evaluation of suspected pulmonary embolism? *Am J Roentgenol* 1993; 161: 1289-92.
- [211] Oudkerk M, van Beek JR, van Putten WLJ, Büller HR. Cost-effectiveness analysis of various strategies in the diagnostic management of pulmonary embolism. *Arch Intern Med* 1993; 153: 947-54.
- [212] Hull RD, Feldstein W, Stein PD, Pineo GF. Cost-effectiveness of pulmonary embolism diagnosis. *Arch Intern Med* 1996; 156: 68-72.
- [213] Perrier A, Buswell L, Bounameaux H *et al.* Cost-effectiveness of noninvasive diagnostic aids in suspected pulmonary embolism. *Arch Intern Med* 1997; 157: 2309-16.
- [214] Hull RD, Raskob GE, Ginsberg JS *et al.* A noninvasive strategy for the treatment of patients with suspected pulmonary embolism. *Arch Intern Med* 1994; 154: 289-97.
- [215] Lagerstedt CI, Fagher BO, Olsson CG, Öqvist BW. Need for long-term anticoagulant treatment in symptomatic calf-vein thrombosis. *Lancet* 1985; 2: 515-8.
- [216] Kakkar VV, Flanc C, Howe CT, Clarke MB. Natural history of postoperative deep-vein thrombosis. *Lancet* 1969; 2: 230-2.
- [217] Bounameaux H, de Moerloose P, Perrier A, Miron MJ. D-dimer testing in suspected venous thromboembolism: an update. *Q J Med* 1997; 90: 437-42.
- [218] Righini M, Goehring C, Bounameaux H, Perrier A. Influence of age on performances of common diagnostic tests in suspected pulmonary embolism. *Am J Med* 2000 (in press).
- [219] Miron MJ, Perrier A, Bounameaux H *et al.* Contribution of noninvasive evaluation to the diagnosis of pulmonary embolism in hospitalized patients. *Eur Respir J* 1999; 13: 1365-70.
- [220] Ginsberg JS, Wells PS, Kearon C *et al.* Sensitivity and specificity of a rapid whole-blood assay for D-dimer in the diagnosis of pulmonary embolism. *Ann Intern Med* 1998; 129: 1006-11.
- [221] Bounameaux H, de Moerloose P, Perrier A, Reber G. Plasma measurement of D-dimer as diagnostic aid in

- suspected venous thromboembolism: an overview. *Thromb Haemost* 1994; 71: 1–6.
- [222] Van Beek EJ, van den Ende B, Berckmans RJ *et al.* A comparative analysis of D-dimer assays in patients with clinically suspected pulmonary embolism. *Thromb Haemost* 1993; 70: 408–13.
- [223] De Moerloose P, Desmarais S, Bounameaux H *et al.* Contribution of a new, rapid, individual and quantitative automated D-dimer ELISA to exclude pulmonary embolism. *Thromb Haemost* 1996; 75: 11–3.
- [224] Oger E, Leroyer C, Bressollette L *et al.* Evaluation of a new, rapid, and quantitative D-Dimer test in patients with suspected pulmonary embolism. *Am J Respir Crit Care Med* 1998; 158: 65–70.
- [225] Reber G, Bounameaux H, Perrier A, de Moerloose P. Performances of a new, rapid and automated microlatex D-dimer assay for the exclusion of pulmonary embolism in symptomatic outpatients. *Thromb Haemost* 1998; 80: 719–20.
- [226] Ginsberg JS, Wells PS, Brill-Edwards P *et al.* Application of a novel and rapid whole blood assay for D-Dimer in patients with clinically suspected pulmonary embolism. *Thromb Haemost* 1995; 73: 379–86.
- [227] Turkstra F, van Beek JR, ten Cate JW, Büller HR. Reliable rapid blood test for the exclusion of venous thromboembolism in symptomatic outpatients. *Thromb Haemost* 1996; 76: 9–11.
- [228] Carson JL, Kelley MA, Duff A, Palevitch M. The clinical course of pulmonary embolism. *N Engl J Med* 1992; 326: 1240–5.
- [229] Miron MJ, Perrier A, Bounameaux H *et al.* Contribution of noninvasive evaluation to the diagnosis of pulmonary embolism in hospitalized patients. *J Gen Intern Med* 1998; 13: 20.
- [230] McIntyre KM, Sasahara AA. Determinants of right ventricular function and hemodynamics after pulmonary embolism. *Chest* 1974; 65: 534–43.
- [231] Azarian R, Wartski M, Collignon MA *et al.* Lung perfusion scans and hemodynamics in acute and chronic pulmonary embolism. *J Nucl Med* 1997; 38: 980–3.
- [232] Molloy WD, Lee KY, Girling L, Schick GU, Prewitt RM. Treatment of shock in a canine model of pulmonary embolism. *Am Rev Respir Dis* 1984; 130: 870–4.
- [233] Adams JE, Siegel BA, Goldstein ML *et al.* Elevation of CK-MB following pulmonary embolism. *Chest* 1992; 101: 1203–6.
- [234] Ramirez-Rivera A, Gutierrez-Fajardo P, Jèrjes-Sanchez C *et al.* Acute right myocardial infarction without significant obstructive coronary lesions secondary to massive pulmonary embolism (Abstr). *Chest* 1993; 104: 80S.
- [235] Belenkie I, Dani R, Smith ER, Tyberg JV. Ventricular interaction during experimental acute pulmonary embolism. *Circulation* 1988; 78: 761–8.
- [236] Belenkie I, Dani R, Smith ER, Tyberg JV. Effects of volume loading during experimental acute pulmonary embolism. *Circulation* 1989; 80: 178–88.
- [237] Ozier Y, Dubourg O, Farcot JC, Bazin M, Jardin F, Margairaz A. Circulatory failure in acute pulmonary embolism. *Intensive Care Med* 1984; 10: 91–7.
- [238] Mercat A, Diehl JL, Meyer G, Teboul J-L, Sors H. Hemodynamic effects of fluid loading in acute massive pulmonary embolism. *Crit Care Med* 1999; 27: 540–4.
- [239] Jardin F, Gurdjian F, Margairaz A. Effet délétère de l'isoprénaline au cours d'une embolie pulmonaire massive. *Nouv Presse Med* 1977; 6: 1878.
- [240] Molloy DW, Lee KY, Jones D, Penner B, Prewitt RM. Effects of noradrenaline and isoproterenol on cardiopulmonary function in a canine model of acute pulmonary hypertension. *Chest* 1985; 88: 432–5.
- [241] Ducas J, Stitz M, Gu S, Schick U, Prewitt RM. Pulmonary vascular pressure-flow characteristics: effects of dopamine before and after pulmonary embolism. *Am Rev Respir Dis* 1992; 148: 307–12.
- [242] Jardin F, Genevray B, Brun-Ney D, Margairaz A. Dobutamine. A hemodynamic evaluation in pulmonary embolism shock. *Crit Care Med* 1985; 13: 1009–12.
- [243] Boulain T, Lanotte R, Legras A *et al.* Efficacy of epinephrine therapy in shock complicating pulmonary embolism. *Chest* 1993; 104: 300–2.
- [244] Delcroix M, Melot C, Lejeune P, Leeman M, Naeije R. Effects of vasodilators on gas exchange in acute canine embolic pulmonary hypertension. *Anesthesiology* 1990; 72: 77–84.
- [245] Huet Y, Brun-Buisson C, Lemaire F, Teisseire B, Lhoste F, Rapin M. Cardiopulmonary effects of ketanserin infusion in human pulmonary embolism. *Am Rev Respir Dis* 1987; 135: 114–7.
- [246] Böttiger BW, Motsch J, Dörsam J *et al.* Inhaled nitric oxide selectively decreases pulmonary artery pressure and pulmonary vascular resistance following acute massive pulmonary microembolism in piglets. *Chest* 1996; 110: 1041–7.
- [247] Capellier G, Jacques T, Balay P *et al.* Inhaled nitric oxide in patients with pulmonary embolism. *Intensive Care Med* 1997; 1089–92.
- [248] Urokinase Pulmonary Embolism Trial (UPET). A national cooperative study. *Circulation* 1973; 47 (Suppl II): 1–130.
- [249] Jardin F, Gurdjian F, Desfonds P, Fouilladieu JL, Margairaz A. Hemodynamic factors influencing arterial hypoxemia in massive pulmonary embolism with circulatory failure. *Circulation* 1979; 59: 909–12.
- [250] Alpert JS, Smith R, Carlson J *et al.* Mortality in patients treated for pulmonary embolism. *JAMA* 1976; 236: 1477–80.
- [251] Goldhaber SZ, Haire WD, Feldstein ML *et al.* Alteplase versus heparin in acute pulmonary embolism: randomised trial assessing right-ventricular function and pulmonary perfusion. *Lancet* 1993; 341: 507–11.
- [252] Konstantinides S, Geibel A, Olschewski M *et al.* Association between thrombolytic treatment and the prognosis of hemodynamically stable patients with major pulmonary embolism. *Circulation* 1997; 96: 882–8.
- [253] Dalla-Volta S, Palla A, Santolicandro A *et al.* PAIMS 2: alteplase combined with heparin versus heparin in the treatment of acute pulmonary embolism. Plasminogen activator italian multicenter study 2. *J Am Coll Cardiol* 1992; 20: 520–6.
- [254] Tibbutt DA, Davies JA, Anderson JA *et al.* Comparison by controlled clinical trial of streptokinase and heparin in treatment of life-threatening pulmonary embolism. *Br Med J* 1974; 1: 343–7.
- [255] Stein PD, Hull RD, Raskob G. Risks for major bleeding from thrombolytic therapy in patients with acute pulmonary embolism. *Ann Intern Med* 1994; 121: 313–7.
- [256] Mikkola KM, Patel SR, Parker JA, Grodstein F, Goldhaber SZ. Increasing age is a major risk factor for hemorrhagic complications after pulmonary embolism thrombolysis. *Am Heart J* 1997; 134: 69–72.
- [257] Meyer G, Charbonnier B, Stern M, Brochier M, Sors H. Thrombolysis in acute pulmonary embolism. In: Julian DG, Kubler W, Norris RM, Swan HJ, Collen D, Verstraete M, eds. *Thrombolysis in cardiovascular disease*. New-York, Marcel Dekker, 1989: 337–60.
- [258] Meyer G, Gisselbrecht M, Diehl JL, Journois D, Sors H. Incidence and predictors of major hemorrhagic complications from thrombolytic therapy in patients with massive pulmonary embolism. *Am J Med* 1998; 105: 472–7.
- [259] Kanter DS, Mikkola KM, Patel SR, Parker JA, Goldhaber SZ. Thrombolytic therapy for pulmonary embolism. Frequency of intracranial hemorrhage and associated risk factors. *Chest* 1997; 111: 1241–5.
- [260] Levine M, Hirsh J, Weitz J *et al.* A randomized trial of a single bolus dosage regimen of recombinant tissue plasminogen activator in patients with acute pulmonary embolism. *Chest* 1990; 98: 1473–9.
- [261] The PIOPED Investigators. Tissue plasminogen activator for the treatment of acute pulmonary embolism. *Chest* 1990; 97: 528–33.

- [262] Ly B, Arnesen H, Eie H, Hol R. A controlled clinical trial of streptokinase and heparin in the treatment of major pulmonary embolism. *Acta Med Scand* 1978; 203: 465–70.
- [263] Jerjes-Sanchez C, Ramirez-Rivera A, De Lourdes Garcia M *et al.* Streptokinase and heparin versus heparin alone in massive pulmonary embolism: A randomized controlled trial. *J Thromb Thrombolys* 1995; 2: 227–9.
- [264] Goldhaber SZ, Heit J, Sharma GVRK *et al.* Randomised controlled trial of recombinant tissue plasminogen activator versus urokinase in the treatment of acute pulmonary embolism. *Lancet* 1988; 2: 293–8.
- [265] Meyer G, Sors H, Charbonnier B *et al.* Effects of intravenous urokinase versus alteplase on total pulmonary resistance in acute massive pulmonary embolism: A European multicenter double-blind trial. *J Am Coll Cardiol* 1992; 19: 239–45.
- [266] Sors H, Pacouret G, Azarian R, Meyer G, Charbonnier B, Bassand JP, Simonneau G. Hemodynamic effects of bolus versus two hour infusion of alteplase in acute massive pulmonary embolism. A randomized controlled multicenter trial. *Chest* 1994; 106: 712–7.
- [267] Goldhaber SZ, Agnelli G, Levine MN. Reduced dose bolus alteplase vs conventional alteplase infusion for pulmonary embolism thrombolysis. An international multicenter randomized trial. *Chest* 1994; 106: 718–24.
- [268] Meneveau N, Schiele F, Metz D *et al.* Comparative efficacy of a two hour regimen of streptokinase versus alteplase in acute massive pulmonary embolism: immediate clinical and hemodynamic outcome and one-year follow-up. *J Am Coll Cardiol* 1998; 32: 1057–63.
- [269] The Columbus investigators. Low-molecular-weight heparin in the treatment of patients with venous thromboembolism. *N Engl J Med* 1997; 337: 657–62.
- [270] Simonneau G, Sors H, Charbonnier B *et al.* A comparison of low-molecular-weight heparin with unfractionated heparin for acute pulmonary embolism. *N Engl J Med* 1997; 337: 663–9.
- [271] Urokinase-Streptokinase Embolism Trial. A cooperative study. Phase 2 results. *JAMA* 1974; 229: 1606–13.
- [272] The UKEP study. Multicentre clinical trial on two local regimens of urokinase in massive pulmonary embolism. *Eur Heart J* 1987; 8: 2–10.
- [273] Goldhaber SZ, Kessler CM, Heit JA *et al.* Recombinant tissue-type plasminogen activator versus a novel dosing regimen of urokinase in acute pulmonary embolism: a randomized controlled multicenter trial. *J Am Coll Cardiol* 1992; 20: 24–30.
- [274] Berger RL, Ashraf MM. Letters to the editor: Pulmonary embolectomy. *J Thorac Cardiovasc Surg* 1991; 94: 154–6.
- [275] Vieillard-Baron A, Qanadli SD, Antakly Y *et al.* Transesophageal echocardiography for the diagnosis of pulmonary embolism with acute cor pulmonale: a comparison with radiological procedures. *Intensive Care Med* 1998; 24: 429–33.
- [276] Meyer G, Tamisier D, Sors H *et al.* Pulmonary embolectomy: a 20 year experience at one center. *Ann Thorac Surg* 1991; 51: 232–6.
- [277] Robinson RJ, Fehrenbacher J, Brown JW, Madura JA, King H. Emergent pulmonary embolectomy: the treatment for massive pulmonary embolus. *Ann Thorac Surg* 1986; 42: 52–5.
- [278] Beall AC. Pulmonary embolectomy. *Ann Thorac Surg* 1991; 51: 179.
- [279] Bauer EP, Laske A, von Segesser L, Carrel T, Turina M. Early and late results after surgery for massive pulmonary embolism. *Thorac Cardiovasc Surg* 1991; 39: 353–6.
- [280] Von Segesser L, Bauer E, Jenni R, Turina M. Improved forceps for pulmonary embolectomy. *Ann Thorac Surg* 1991; 52: 1185–6.
- [281] Ohteki H, Norita H, Sakai M, Narita Y. Emergency pulmonary embolectomy with percutaneous cardiopulmonary bypass. *Ann Thorac Surg* 1997; 63: 1584–6.
- [282] Mohan CR, Hoballah JJ, Sharp WJ, Kresowik TF, Lu CT, Corson JD. Comparative efficacy and complications of vena caval filters. *J Vasc Surg* 1995; 21: 235–46.
- [283] Haire WD. Vena caval filters for the prevention of pulmonary embolism. *N Engl J Med* 1998; 338: 463–4.
- [284] Doerge HC, Schoendube FA, Loeser H, Walter M, Messmer BJ. Pulmonary embolectomy: review of a 15 year experience and role in the age of thrombolytic therapy: early and late results. *Thorac Cardiovasc Surg* 1999; 47: 9–13.
- [285] Stulz P, Schläpfer R, Feer R, Habicht J, Grädel E. Decision making in the surgical treatment of massive pulmonary embolism. *Eur J Cardio-thorac Surg* 1994; 8: 188–93.
- [286] Meyer G, Diehl JL, Philippe B, Reynaud P, Sors H. Pulmonary embolectomy in pulmonary embolism; surgery and endoluminal techniques. *Arch Mal Couer Vaiss* 1995; 88: 1777–80.
- [287] Greenfield LJ, Proctor MC, Williams DM *et al.* Long-term experience with transvenous catheter pulmonary embolectomy. *J Vasc Surg* 1993; 18: 450–8.
- [288] Timsit JF, Reynaud P, Meyer G, Sors H. Pulmonary embolectomy by catheter device in massive pulmonary embolism. *Chest* 1991; 100: 655–8.
- [289] Hyers TM, Agnelli G, Hull RD, Weg JG, Morris TA, Samama M, Tapson V. Anti-thrombotic therapy for venous thromboembolic disease. *Chest* 1998; 114/5 (Suppl): 561S–78S.
- [290] Brandjes DPM, Heijboer H, Buller HR, de Rijk M, Jagt H, ten Cate JW. Acenocoumarol and heparin compared with acenocoumarol alone in the initial treatment of proximal vein thrombosis. *N Engl J Med* 1992; 327: 1485–9.
- [291] Raschke RA, Reilly BM, Guidry JR *et al.* The weight-based heparin dosing nomogram compared with a standard care nomogram a randomized controlled trial. *Ann Intern Med* 1993; 119: 874–81.
- [292] Anand SS, Bates S, Ginsberg JS *et al.* Recurrent venous thrombosis and heparin therapy: an evaluation of the importance of early activated partial thromboplastin times. *Arch Intern Med* 1999; 159: 2029–32.
- [293] Levine MN, Hirsh J, Gent M *et al.* A randomized trial comparing activated thromboplastin time with heparin assay in patients with acute venous thromboembolism requiring large daily doses of heparin. *Arch Intern Med* 1994; 154: 49–56.
- [294] Young E, Prins M, Levine MN, Hirsh J. Heparin binding to plasma proteins: an important mechanism for heparin resistance. *Thromb Haemost* 1992; 67: 639–43.
- [295] Levine MN, Raskob G, Landerfeld S, Hirsh J. Hemorrhagic complications of anticoagulant treatments. *Chest* 1995; 108 (Suppl): 276S–90S.
- [296] Hirsh J, Raschke R, Warkentin TE, Dalen JE, Deykin D, Poller J. Heparin: mechanism of action, pharmacokinetics, dosing considerations, monitoring efficacy, and safety. *Chest* 1995; 108 (Suppl): 258S–75S.
- [297] Warkentin TF, Levine MN, Hirsh J *et al.* Heparin induced thrombocytopenia in patients treated with low molecular weight heparin or unfractionated heparin. *N Engl J Med* 1995; 332: 1330–5.
- [298] Koopman MM, Prandoni P, Piovella F *et al.* Treatment of venous thrombosis with intravenous unfractionated heparin administered in the hospital as compared with subcutaneous low molecular weight heparin administered at home. The TASMMAN Study group. *N Engl J Med* 1996; 334: 682–7.
- [299] Levine MN, Gent M, Hirsh J *et al.* A comparison of low molecular weight heparin administered primarily at home with unfractionated heparin administered in the hospital for proximal deep vein thrombosis. *N Engl J Med* 1996; 334: 677–81.
- [300] Lindmarker P, Holmstrom M. Use of low molecular weight heparine (dalteparin) once daily, for the treatment of deep vein thrombosis. A feasibility and health economic study in an outpatient setting. *J Intern Med* 1996; 240: 395–401.

- [301] Koopman MMW, Buller HR. Low molecular weight heparins in the treatment of venous thromboembolism. *Ann Intern Med* 1988; 108: 1037-9.
- [302] Kearon C, Hirsh J. Management of anticoagulation before and after elective surgery. *N Engl J Med* 1997; 336: 1506-11.
- [303] Thomson AJ, Walker ID, Greer IA. Low molecular weight heparins for immediate management of thromboembolic disease in pregnancy. *Lancet* 1998; 352: 1904.
- [304] Prandoni P, Lensing AWA, Cogo A *et al.* The long term clinical course of acute deep venous thrombosis. *Ann Intern Med* 1996; 125: 1-7.
- [305] Khamashta MA, Cuadrado MJ, Mujie F, Taub NA, Hunt BJ, Hughes GRV. The management of thrombosis in the antiphospholipid antibody syndrome. *N Engl J Med* 1995; 332: 993-7.
- [306] Moll S, Ortel TL. Monitoring warfarin therapy in patients with lupus anticoagulants. *Ann Intern Med* 1997; 127: 177-85.
- [307] Warkentin TE, Kelton JG. A 14-year study of heparin-induced thrombocytopenia. *Am J Med* 1996; 101: 502-7.
- [308] Warkentin TE, Elavathil L, Hayward CPM, Johnston MA, Russett H, Kelton JG. The pathogenesis of venous limb gangrene associated with heparin-induced thrombocytopenia. *Ann Intern Med* 1997; 127: 804-12.
- [309] Magnani HN. Heparin-induced thrombocytopenia (HIT): an overview of 230 patients treated with Orgaran. *Thromb Haemost* 1993; 70: 554-61.
- [310] Schwatz RP Jr, Becker JCP, Brooks RL *et al.* The preclinical and clinical pharmacology of novastan (Argatroban): a small molecule, direct thrombin inhibitor. *Clin Appl Thromb Hemost* 1997; 3: 1-15.
- [311] Hirsch J, Dalen JE, Anderson DR *et al.* Oral anticoagulants. Mechanism of action, clinical effectiveness and optimal therapeutic range. *Chest* 1998; 114(5) (Suppl): 445S-69S.
- [312] Harrison L, Johnston M, Massicotte MP *et al.* Comparison of 5 mg and 10 mg loading doses in initiation of warfarin therapy. *Ann Intern Med* 1997; 126: 133-6.
- [313] Gallus A, Jackaman J, Tillett J *et al.* Safety and efficacy of warfarin started early after submassive venous thrombosis or pulmonary embolism. *Lancet* 1986; 2: 1293-6.
- [314] Hull RD, Raskob GE, Rosenblum D *et al.* Heparin for 5 days as compared with 10 days in the initial treatment of proximal venous thrombosis. *N Engl J Med* 1990; 322: 1260-4.
- [315] Hull RD, Hirsh J, Jay R *et al.* Different intensities of oral anticoagulant therapy in the treatment of proximal vein thrombosis. *N Engl J Med* 1982; 307: 1676-81.
- [316] Levine MN, Hirsh J, Gent M *et al.* Optimal duration of oral anticoagulant therapy. A randomised trial comparing four weeks with three months of warfarin in patients with proximal deep vein thrombosis. *Thromb Haemost* 1995; 74: 606-11.
- [317] Prandoni P, Lensing AWA, Buller HR *et al.* Deep vein thrombosis and the incidence of subsequent symptomatic cancer. *N Engl J Med* 1992; 327: 1128-33.
- [318] Research Committee of the British Thoracic Society. Optimum duration of anticoagulation for deep vein thrombosis and pulmonary embolism. *Lancet* 1992; 340: 873-6.
- [319] Schulman S, Rhedin AS, Lindmarker P *et al.* A comparison of six weeks with six months of oral anticoagulant therapy after a first episode of venous thromboembolism. *N Engl J Med* 1995; 332: 1661-5.
- [320] Kearon C, Gent M, Hirsh J *et al.* A comparison of three months of anticoagulation with extended anticoagulation for a first episode of idiopathic venous thromboembolism. *N Engl J Med* 1999; 340: 901-7.
- [321] Schulman S, Granquist S, Holmström M *et al.* The duration of oral anticoagulant therapy after a second episode of venous thromboembolism. *N Engl J Med* 1997; 336: 393-8.
- [322] Landefeld CS, Rosenblatt MW, Goldman L. Bleeding in outpatients treated with warfarin: relation to the prothrombin time and important remediable lesions. *Am J Med* 1989; 87: 153-9.
- [323] Crowther MA, Donovan D, Harrison L *et al.* Low dose oral vitamin K reliably reverses over-anticoagulation due to warfarin. *Thromb Haemost* 1998; 79: 1116-8.
- [324] Brochmans AW, Bertina RM, Loeliger EA *et al.* Protein C and the development of skin necrosis during anticoagulant therapy. *Thromb Haemost* 1983; 49: 244-51.
- [325] Grimaudo V, Gueissaz F, Hauert J *et al.* Necrosis of skin induced by coumarin in a patient deficient in protein S. *Br Med J* 1989; 298: 233-4.
- [326] Everett RN, Jones FL. Warfarin induced skin necrosis: a cutaneous sign of malignancy? *Post Grad Med* 1983; 79: 97-103.
- [327] Ginsberg JS, Hirsh J, Turner DC, Levine MN, Burrows R. Risks to the foetus of anticoagulant therapy during pregnancy. *Thromb Haemost* 1989; 61: 197-203.
- [328] Sanson BJ, Lensing AWA, Prinz MH *et al.* Safety of low molecular weight heparin in pregnancy: a systematic review. *Thromb Haemost* 1999; 81: 668-72.
- [329] Tadavarthy SM, Castaneda-Zuniga W, Salomonowitz E *et al.* Kimray Greenfield vena cava filters: percutaneous introduction. *Radiology* 1984; 151: 525-6.
- [330] Greenfield LJ, Proctor MC. Current indications for caval interruption should they be liberalized in view of improving technology? *Semin Vasc Surg* 1996; 9: 50-8.
- [331] Thery C, Asseman P, Amrouni N *et al.* Use of a new removable vena cava filter in order to prevent pulmonary embolism in patients submitted to thrombolysis. *Eur Heart J* 1990; 11: 334-41.
- [332] Boyyn G, Gory P, Reynaud P, Ricco JB. The tempofilter®: a multicenter study of a new temporary caval filter implantable for up to six weeks. *Ann Vasc Surg* 1997; 11: 520-8.
- [333] Greenfield LJ, Cho KJ, Proctor M *et al.* Results of a multicenter study of the modified hook-titanium Greenfield filter. *J Vasc Surg* 1991; 14: 253-7.
- [334] Ricco JB, Crochet D, Sebicotte P *et al.* Percutaneous transvenous caval interruption with the 'LGM' filter: early results of a multicenter trial. *Ann Vasc Surg* 1988; 2: 242-7.
- [335] Simon M, Athanasoulis CA, Kim D *et al.* Simon Nitinol inferior vena cava filter: initial clinical experience. *Radiology* 1989; 172: 99-103.
- [336] Roehm JOF Jr. The Bird's nest filter: a new percutaneous transcatheter inferior vena cava filter. *J Vasc Surg* 1984; 1: 498-501.
- [337] Greenfield LJ, Cho KJ, Proctor M, Sobel M, Sham S, Wingo J. Late results of supra-renal Greenfield filter placement. *Arch Surg* 1992; 127: 969-73.
- [338] Stewart JR, Peyton JWR, Crute LL, Greenfield LJ. Clinical results of suprarenal placement of the Greenfield vena cava filter. *Surgery* 1982; 92: 1-4.
- [339] Ballew KA, Philbrick JT, Becker DM. Vena cava filter devices. *Clin Chest Med* 1995; 16: 295-305.
- [340] Becker DM, Philbrick JT, Selby JB. Inferior vena cava filters, indications, safety, effectiveness. *Arch Intern Med* 1992; 152: 1985-94.
- [341] Crochet DP, Stora O, Ferry D *et al.* Vena Tech-LGM filter: long term results of a prospective study. *Radiology* 1993; 188: 857-60.
- [342] Decousus H, Leizorovicz A, Parent F *et al.* A clinical trial of vena cava filters with prevention of pulmonary embolism in patients with proximal deep vein thrombosis. *N Engl J Med* 1998; 338: 409-15.
- [343] Kolachalam RB, Julian TB. Clinical presentation of thrombosed Greenfield filters. *Vasc Surg* 1990; 9: 666-70.
- [344] Castellani L, Nicaise M, Pietri J *et al.* Transvenous interruption of the inferior vena cava. *Int Angiol* 1987; 6: 299-306.
- [345] Roehm JOF Jr, Johnsrude IS, Barth MH, Gianturco C. The Bird's nest inferior vena cava filter: progress report. *Radiology* 1988; 168: 745-9.
- [346] Golveke PJ, Garrett WV, Thompson JE *et al.* Interruption of the vena cava by means of the Greenfield filter: expanding the indications. *Surgery* 1988; 103: 111-7.

- [347] Patton JH, Fabian TC, Cruce MA, Minard G, Pritchard EF, Kudsk KA. Prophylactic Greenfield filters: acute complications and long term follow-up. *J Trauma* 1996; 41: 231–7.
- [348] Rogers FB, Strindberg G, Shackford SR *et al.* Five year follow-up of prophylactic vena cava filters in high-risk trauma patients. *Arch Surg* 1998; 133: 406–11.
- [349] Vos LD, Tielbeek AV, Bom EP, Gooszen HC, Vroegindeweij D. The Gunther temporary inferior vena cava filter for short term protection against pulmonary embolism. *Cardiovasc Intervent Radiol* 1997; 20: 91–7.
- [350] Rochat RW, Koonin LM, Atrash HK, Jewett JF. Maternal mortality in the United States: report from the Maternal Mortality Collaborative. *Obstet Gynecol* 1988; 72: 91–7.
- [351] Sachs BP, Brown DA, Driscoll SG *et al.* Maternal mortality in Massachusetts. Trends and prevention. *N Engl J Med* 1987; 316: 667–72.
- [352] Bergqvist A, Bergqvist D, Hallbook T. Deep vein thrombosis during pregnancy. A prospective study. *Acta Obstet Gynecol Scand* 1983; 62: 443–8.
- [353] Kierkegaard A. Incidence and diagnosis of deep vein thrombosis associated with pregnancy. *Acta Obstet Gynecol Scand* 1983; 62: 239–43.
- [354] Rutherford S, Montoro M, McGehee W, Strong T. Thromboembolic disease associated with pregnancy: a 11-year review. *Am J Obstet Gynecol* 1991; 164: 286.
- [355] Macklon NS, Greer IA. Venous thromboembolic disease in obstetrics and gynaecology: the Scottish experience. *Scott Med J* 1996; 41: 83–6.
- [356] Ikard RW, Ueland K, Folse R. Lower limb venous dynamics in pregnant women. *Surg Gynecol Obstet* 1971; 132: 483–8.
- [357] Macklon NS, Greer IA, Bowman AW. An ultrasound study of gestational and postural changes in the deep venous system of the leg in pregnancy. *Br J Obstet Gynaecol* 1997; 104: 191–7.
- [358] Ginsberg JS, Brill-Edwards P, Burrows RF *et al.* Venous thrombosis during pregnancy: leg and trimester of presentation. *Thromb Haemost* 1992; 67: 519–20.
- [359] British Thoracic Society Consensus Committee. Suspected acute pulmonary embolism: a practical approach. *Thorax* 1997; 52: S2–S21.
- [360] Ang CK, Tan TH, Walters WA, Wood C. Postural influence on maternal capillary oxygen and carbon dioxide tension. *Br Med J* 1969; 4: 201–3.
- [361] Ginsberg S, Hirsh J, Rainbow AJ, Coates G. Risks to the fetus of radiologic procedures used in the diagnosis of maternal venous thromboembolic disease. *Thromb Haemost* 1989; 61: 189–96.
- [362] Winer-Muram HT, Boone JM, Tankiwale A, Lombardo GL, Russi TJ, Muram D. Helical CT for pregnant patients with suspected pulmonary embolism — is it safe? *Radiology* 1999; 213 (P): 128.
- [363] Francalanci I, Comeglio P, Liotta AA *et al.* D-dimer concentrations during normal pregnancy, as measured by ELISA. *Thromb Res* 1995; 78: 399–405.
- [364] Omri A, Delaloye JF, Andersen H, Bachmann F. Low molecular weight heparin Novo (LHN-1) does not cross the placenta during the second trimester of pregnancy. *Thromb Haemost* 1989; 61: 55–6.
- [365] Lensing AW, Prins MH, Davidson BL, Hirsh J. Treatment of deep venous thrombosis with low-molecular-weight heparins. A meta-analysis. *Arch Intern Med* 1995; 155: 601–7.
- [366] Melissari E, Parker CJ, Wilson NV *et al.* Use of low molecular weight heparin in pregnancy. *Thromb Haemost* 1992; 68: 652–6.
- [367] Shaul WL, Emery H, Hall JG. Chondrodysplasia punctata and maternal warfarin use during pregnancy. *Am J Dis Child* 1975; 129: 360–2.
- [368] Shaul WL, Hall JG. Multiple congenital anomalies associated with oral anticoagulants. *Am J Obstet Gynecol* 1977; 127: 191–8.
- [369] Hall JG, Pauli RM, Wilson KM. Maternal and fetal sequelae of anticoagulation during pregnancy. *Am J Med* 1980; 68: 122–40.
- [370] Ginsberg JS, Hirsh J. Use of antithrombotic agents during pregnancy. *Chest* 1998; 114: 524S–30S.
- [371] Dahlman TC, Hellgren MS, Blomback M. Thrombosis prophylaxis in pregnancy with use of subcutaneous heparin adjusted by monitoring heparin concentration in plasma. *Am J Obstet Gynecol* 1989; 161: 420–5.
- [372] Chan WS, Ginsberg JS. Management of venous thromboembolism in pregnancy. In: Oudkerk M, Van Beek EJR, Ten Cate JW, eds. *Pulmonary Embolism*. Berlin: Blackwell Science, 1999: 430–41.
- [373] Turrentine MA, Braems G, Ramirez MM. Use of thrombolytics for the treatment of thromboembolic disease during pregnancy. *Obstet Gynecol Surv* 1995; 50: 534–41.

## Appendix 1: ESC Board and SCI Committee Reviewers

Lars Rydén MD, FESC, Department of Cardiology, Karolinska Hospital, Stockholm, Sweden  
 Maarten Simoons MD, FESC, Thoraxcenter, University Hospital Rotterdam, Netherlands  
 Ali Oto, MD, FESC, Medical Office, Cankaya, Ankara, Turkey  
 Jean-Pierre Bassand MD, FESC, Service de Cardiologie, Pole Coeur-Poumons, C.H.U. Jean Minjoz, Besancon, France  
 Raimund Erbel MD, FESC, Abteilung fur Kardiologie, Universitat GSH Essen, Germany  
 Barbara Mulder, Academic Medical Centre, Amsterdam, NL

## Appendix 2: ESC Task Force on Pulmonary Embolism

### Core Writing Group:

Edwin J.R. van Beek MD PhD FRCR, Section of Academic Radiology, Royal Hallamshire Hospital, Sheffield, United Kingdom (*Editor*)  
 Bernard Charbonnier MD, FESC, Department of Cardiology, University Hospital Trousseau, Tours, France  
 Guy Meyer, MD, Respiratory and Intensive Care, Hôpital Laennec, Paris, France  
 Mario Morpurgo MD, FESC, Ospedale San Carlo Borromeo, Milano, Italy  
 Antonio Palla, MD, Dipartimento Cardio Toracico Università di Pisa, Italy  
 Arnaud Perrier, MD, PD, Medical Clinics 1 and 2, Department of Internal Medicine, Geneva University Hospital, Geneva, Switzerland  
 Adam Torbicki MD, FESC, Department of Chest Medicine, Institute of Tuberculosis and Lung Diseases, Warszawa, Poland (*Chair*)

### Members:

Nazzareno Galie, MD, FESC, Institute of Cardiology, University of Bologna, Italy (I)

Günter Görge MD, FESC, Department of Cardiology, Lung Disease, Angiology, and Intensive Care Klinikum Saarbrücken, University of Saarland, Saarbrücken, Germany

Christian J. Herold, MD Department of Diagnostic Radiology, I University of Vienna General Hospital, Vienna, Austria (representative *European Association of Radiology*)

Steen E. Husted, MD, DMSc Department of Cardiology and Medicine A

Aarhus Amtssygehus University Hospital of Aarhus, Aarhus C, Denmark

Vlastimil Jezek, MD, FESC, Czech Republic (passed away 1997)

Meinhardt Kneussl MD, FESC, Department of Pneumology I University of Vienna General Hospital, Vienna, Austria (A)

Wolfgang Kasper MD, Medizinische Klinik 1, Kardiologie, Angiologie und Pneumologie, St. Josefs-Hospital, Wiesbaden, Germany

Alyn H. Morice, Academic Department of Medicine, Castle Hill Hospital

Cottingham, Hull, United Kingdom, (representative *European Respiratory Society*)

Dominique Muset, MD, Department of Radiology, Hôpital Antoine-Béclère, Paris XI University, Clamart, France (representative *European Association of Radiology*)

Michel M. Samama, Laboratoire d'Hématologie, Hôtel Dieu, Paris, France

Gerard Simonneau MD, Service de Pneumologie, Hôpital Antoine-Béclère, Paris XI University, Clamart, France

Herve Sors (F), service de pneumologie-réanimation, Hôpital Laennec, Paris, France

Michael de Swiet, Queen Charlottes Hospital for Women, London, United Kingdom

Marko Turina, MD, FESC, Herz- und Gefasschirurgie, Universitatsspital Zurich, Switzerland

*Internal reviewers:*

Gerhard Kronik, MD, FESC, Department of Internal Medicine, Krankenhaus Krems, Krems, Austria

Jiri Widimsky MD, FESC, Department of Cardiology, Klinika Kardiologie IKEM, Praha, Czech Republic.

© 2000 The European Society of Cardiology